VOLUME 2 ISSUE 1 MARCH 2014

EJCO

European Journal of Clinical Orthodontics

ISSN 2283-7272 - Quadrimestrale - Poste Italiane s.p.a. - Spedizione in abbonamento postale- 70% - LO/MI

www.ejco-journal.com

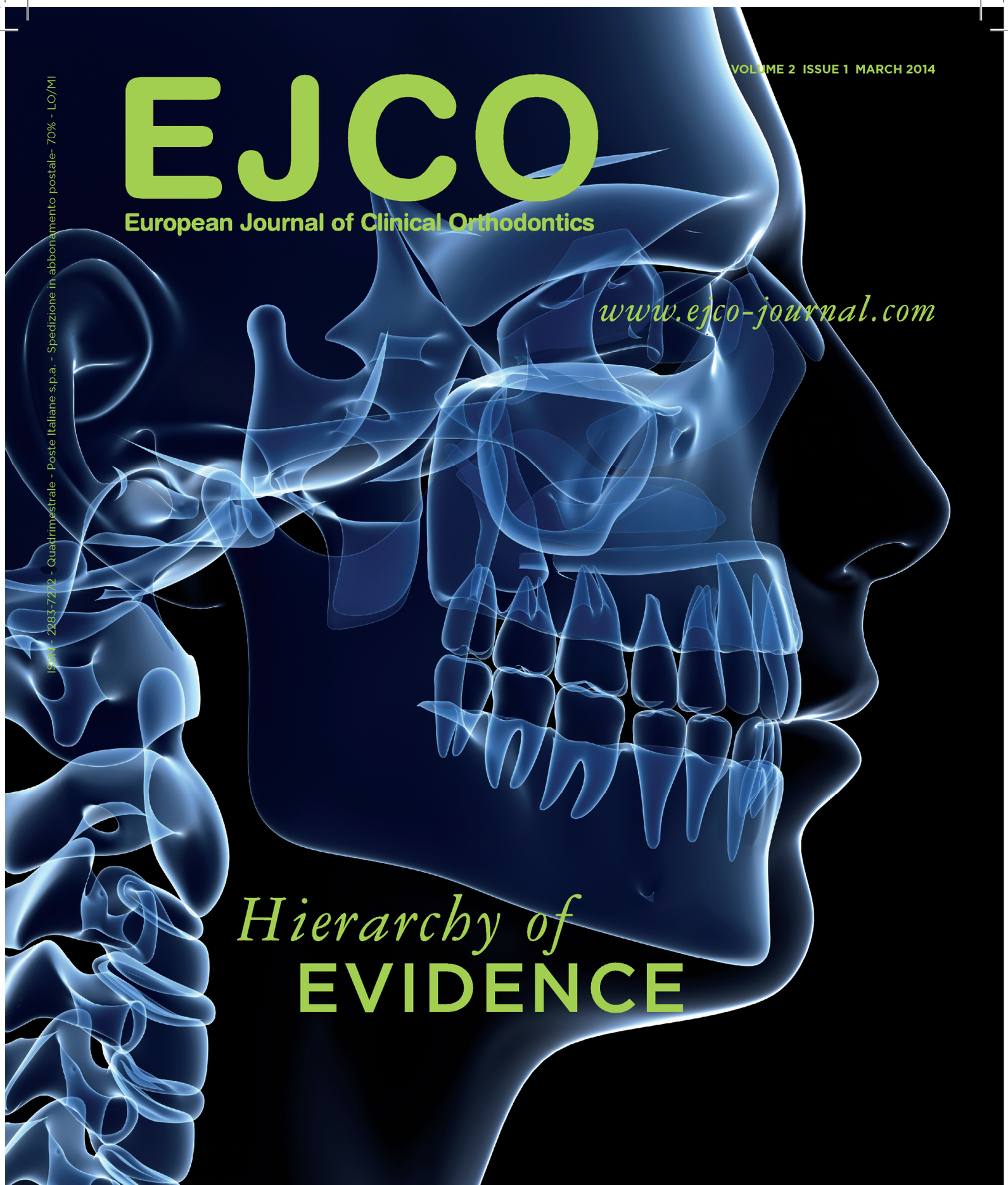

Hierarchy of EVIDENCE

in this issue:

WHO'S WHO
Nigel Harradine

X-RAY ODDITIES
A Stubborn Cuspid

LITERATURE READINGS *for Dummies*
Hierarchy of Evidence

S.I.D.O. SOCIETÀ ITALIANA DI ORTODONZIA

YOUR PERSONAL INVISALIGN® TRAINING PROGRAMME



The Invisalign one-year Training Course programme will open the door for you to a completely new and improved practice experience; with a wider array of services that you can offer to your patients, and a continued learning experience and ongoing support.

The training requirement will consist of a total of 3 Days of Invisalign® Training (Training Course 1, Training Course 2 and MasterClass) at a cost of: **€1.500***

Sign up today:

- **Rome,** March 21st
- **Bari,** April 4th
- **Turin,** April 4th
- **Padua,** May 16th

To learn more and to register simply visit: **www.aligneu.com**
or contact our local marketing office 02 00 62 31 24

invisalign®
Science in Every Smile

* The Invisalign Training Course fee includes the 3 days of training.

European Journal of Clinical Orthodontics
International Journal supported by the Italian Society of Orthodontics (SIDO)
Volume 2, Issue 1

Contents

EDITORIAL
Literature Readings... for Dummies 1
R. Schiavoni

WHO'S WHO
Nigel Harradine 2
Editor: C. Bonapace

WHO'S WHO CLINICAL ARTICLE
From Evidence to Clinical Excellence 3
N. Harradine

CLINICAL ARTICLES
Vertical Control of Second Molars in Fixed Appliance Treatment 10
S. Troiani, M. Gudde

Upper and Lower Incisor Torque and Straight-Wire Appliance 21
R. Spena

X-RAY ODDITIES
A Stubborn Cuspid 33
Editor: V. Grenga

LITERATURE READINGS... *FOR DUMMIES*
Hierarchy of Evidence 35
Editor: B. Oliva

WE TESTED...
VECS™ Palate Expander 36

Editorial Board
- **Editor-in-Chief:** Raffaele Schiavoni, *Italy*
- **Editorial Director** Claudio Lanteri, *Italy*
- **Co-Editor:** Felice Festa, *Italy*
- **Editorial office:** phone + 39 02 58102846 – 83419430 (1) fax: +39 02 93663665 ejco@sido.it
- **Publisher:** SIDO - Società Italiana di Ortodonzia via P. Gaggia 1, Milano, Italy
- **Printer:** UNIGRAFICA S.r.l.
- **Distributed by:** SMC media S.r.l.

Associate Editors:
- Hans-Peter Bantleon, *Austria*
- Alberto Caprioglio, *Italy*
- Giampietro Farronato, *Italy*
- Urban Hägg, *Hong Kong*
- Chung How Kau, *USA*
- Christos Katsaros, *Switzerland*
- Stavros Kiliaridis, *Switzerland*
- Maurizio Manuelli, *Italy*
- Ravindra Nanda, *USA*
- Ramon Perera Grau, *Spain*

Contributing Editors
- Carlo Bonapace *(editor of Who's who column)*, *Italy*
- Gianluigi Fiorillo, *Italy*
- Vittorio Grenga *(editor of X-Ray Oddities column)*, *Italy*
- Bruno Oliva *(editor of Literature Readings for Dummies column)*, *Italy*

Advisory Board
- Silvia Allegrini, *Italy*
- Rossella Contrafatto, *Italy*
- Ewa Czochrowska, *Poland*
- Guy De Paw, *Belgium*
- Rafael García Espejo, *Spain*
- Nathamuni Rengarajan Krishnaswamy, *India*
- Nazan Kücükkeles, *Turkey*
- Pedro Leitao, *Portugal*
- Luca Mergati, *Italy*
- Leondid Persin, *Russia*
- Andreu Puigdollers, *Spain*
- Arni Thordarson, *Iceland*
- Marco Tribò, *Switzerland*
- Peter Van Spronsen, *The Netherlands*
- Carlalberta Verna, *Switzerland*

©2014 Italian Society of Orthodontics (SIDO)
All rights reserved.
This journal and the individual contributions contained in it are protected under copyright by the Italian Society of Orthodontics (SIDO).
No parts of this journal may be reproduced in any material form (including photocopying or storing in any medium by electronic means) and whether transiently or incidentally to some other use of this journal without the written permission of the copyright holder.

Disclaimer
Inclusion of advertising materials in this publication does not constitute a guarantee or endorsement of the quality or value of such product or of the claims made of it by its manufacturer.
Print ISSN 2283-7272
Online Edition www-ejco-journal.com ISSN 2283-9208
Registered at *Registro Stampa at Tribunale Civile e Penale di Milano* n.69 on 18/03/2013

EDITORIAL

Literature Readings... for Dummies



Raffaele Schiavoni
Editor-in-Chief

In our last editorial "A new clinical journal in the era of Evidence-Based Practice" we attempted to identify the current meaning of EBP and the approach to be adopted in the clinical decision-making process. At this point, it therefore becomes essential for clinicians to acquire the background needed to understand the language of clinical research. Not being familiar with clinical study terminology means being unable to understand the value of a research project and, consequently, its relevance to daily clinical practice.

Today's clinician cannot afford to be afflicted by this form of "illiteracy". We decided to give this column, which makes its début with this issue, the tongue-in-cheek title "Literature reading for dummies". Bruno Oliva will allow us, through a series of steps and in the most straightforward manner possible, to understand this new language. The clinical research quality pyramid marks our starting point; let's make sure we do not miss any leg of this journey!

Have a good trip!



© 2014 SIDO



Carlo Bonapace

Private Practice of
Orthodontics, Turin, Italy

WHO'S WHO

In this section we introduce an influential orthodontist who has given a significant contribution to the specialty. An article by the author featuring his landmarks follows.

Correspondence:
Corso Re Umberto, 97
10128 Turin, Italy
e-mail: doctor@studiobonapace.it

Nigel Harradine

Nigel Harradine's route to orthodontics was not a straight one. He did undergraduate degrees in both dentistry and medicine at Guy's Hospital in London, with the intention of being a maxillofacial surgeon. He then got a post as a rotating intern in medicine in London, Ontario, Canada. It was there that he made his decision to become an orthodontist in England.

When his wife Lyn asked him what orthodontics was, he explained to her that it was a branch of dentistry where you had to have good manual skills (unlike many branches of medicine) but you also had to build a long-term motivational relationship with the patient (unlike many branches of surgery).

His specialist training was back in London, England, where, under the influence of Professor Houston, he received a solid grounding in the principles of research and correct scrutiny of the literature.

He then became a senior lecturer at the Eastman Dental Hospital in London, where he supervised master's dissertations, trained registrars at the clinic and finished his further training in complex and multidisciplinary treatments. In 1984, he decided to turn from an academic career and become a clinician who also taught and researched, rather than a teacher and researcher who sometimes saw some patients.

He was appointed to a consultant post at the dental teaching hospital in Bristol, where he developed a particular interest in the latest evolutions in appliances. For example, the straight-wire appliance, twin block appliances, self-ligating brackets, miniscrews and fixed functional appliances have all been a focus of personal clinical use, audit, research and critical scrutiny.

From the early days of computers in orthodontics, he was involved in their clinical application, most notably, in the design and development of a well known program called OPAL.

As a speaker, he has given presentations and held courses in 21 countries.

Away from the chairside and the podium, he has been chairman of a number of national orthodontics and dental committees, founder and inaugural chairman of the British Orthodontic Society Foundation and chairman of the British Orthodontic Society from 2008 to 2011. He is still in charge of the undergraduate programme in orthodontics in Bristol.

Outside interests have included lots of sports: tennis, cycling, skiing and golfing. He even does a lot of singing, both choral and solo recitals; but he finds that what recharges personal batteries wonderfully well is flying: he has flown light aircrafts for almost 20 years!

© 2014 SIDO

From Evidence to Clinical Excellence



Nigel Harradine

Consultant orthodontist and Senior Clinical Lecturer
Bristol Dental Hospital and School, Bristol, United Kingdom

Correspondence:
e-mail: Nigel.Harradine@bristol.ac.uk

Article history
Received: 27/10/2013
Accepted: 21/01/2014

"If clinicians wish to strive for clinical excellence, they must put time and thought into distilling the truest messages from research"

Abstract

We live in an era of unprecedented access to evidence. However, there is also a correspondingly increased need to have a proper insight to all forms and examples of evidence and to be able to ensure that the conclusions drawn from research are the correct or best possible conclusions at that given moment. This paper attempts to pick the best current clinical message from the heterogeneous noise on one area of orthodontics, namely functional appliances; and also aims to suggest a general approach to the interpretation of research in our pursuit of clinical excellence.

Keywords
Functional, growth, compliance

© 2014 SIDO

INTRODUCTION

We live, quite rightly, in an era of appreciation for the need for a sound evidence base for our clinical practice. There is wide appreciation of the hierarchy of evidence and the need for healthy scepticism about the value of both anecdotal clinical examples and enthusiastic endorsements of clinical techniques by well-known clinicians or manufacturers of the equipment and materials we use. However, there is also a perhaps less widely appreciated need to have a proper insight to all the evidence and to be able to ensure that the conclusions drawn from research are the correct or best possible conclusions at that given moment. In particular we need to look closely at the details of the research methodology and decide whether the conclusions are suitable given the data and the conditions of the research. I have personally been directly involved in and a close observer of research in at least two areas of orthodontic practice – the use of functional appliances and self-ligating brackets – which serve to illustrate the challenge of trying to take the best message from all the research and apply it to our practice. This paper attempts to pick the best current clinical message from the heterogeneous noise on one of these topics – functional appliances – and also aims to suggest a general approach to the interpretation of research in our pursuit of clinical excellence.

FUNCTIONAL APPLIANCES

These appliances have been used in orthodontics for approximately a century. They exist in many and varied forms and a number of these attract enthusiastic users and also sceptical or disappointed ex-users. The two core questions are: what changes do they bring about and how practical/successful are they in routine clinical use? The history of research into these questions has followed a pattern representative of all orthodontic research: written and verbal case reports were gradually superseded by case series, then case series using untreated controls or other types of functional appliance for comparison and finally a number of randomised controlled trials (RCTs). I have been an active participant in all these types of reports and research and this at the least enables me to be critical about my own work and to point out the challenge of working out the best message to take to our clinical practice.

EFFECT ON GROWTH

The consensus view is – quite correctly – that the evidence from RCTs supports the evidence from retrospective controlled case series in indicating that the effects on jaw growth are small and temporary[1–4]. A recent systematic review and meta-analysis of the effects of functional appliances on short-term mandibular growth by Marsico et al.[5] concluded that "skeletal changes were statistically significant, but unlikely to be clinically significant". The average increase in total mandibular length was found to be 1.79 mm and the increase in A-P prominence of the mandible is less than that and even less in the longer term. It is perhaps gratifying that a study of which I was a co-author was one of only three found to meet the required standards for inclusion in the meta-analysis. But whilst these studies undoubtedly tell us a large part of the truth on this topic, the question of growth enhancement by functional appliances still remains incompletely resolved for the following reasons.

a) The short duration of functional treatment. The period of treatment in trials and in routine clinical practice is usually shorter than can sensibly be expected to significantly influence jaw growth over the long term. For example, in an RCT where I was a co-author[2,3], we treated the cases until the overjet was completely reduced, which averaged 10 months, and the records were taken after 15 months. It is very reasonable to suggest that this was too short a period to permanently influence jaw growth. However, do we truly wish to extend treatments well beyond a 2-year duration with the aim of achieving more growth modification? Also, is it practicable to sufficiently slow the dental changes and thus extend the functional appliance therapy in the interests of greater influence on growth? Once the overjet is reduced and the appliance is passive, no further growth modification would be anticipated.
b) The age of patients treated. The trials comparing treatment with no treatment were carried out on patients who were significantly younger than the maximum pubertal growth spurt and therefore less likely to influence growth in a given time period. This is also undoubtedly a valid criticism, but the reason why only prepubertal patients have been chosen in such RCTs is because of the ethical unacceptability of leaving a group of, say, 12–13-year-olds untreated for a significant period.

This dilemma is unlikely to be resolved, so what should a clinician conclude?

Well, firstly we can and should look at controlled case series, a type of study held to be less authoritative than RCTs, but not to be disregarded because of that. Whilst RCTs will always struggle ethically to allocate patients at peak growth to a period of no treatment, case series of patients treated at an optimum age of peak growth rate have been informatively compared with the best available untreated controls from other sources (e.g.

© 2014 SIDO

the Bolton study records). These provide evidence that in this peak-growth age group, mandibular length from condylion to gnathion is indeed enhanced by functional appliances, and this evidence is summarised in an excellent review paper[6]. Our enthusiastic response to that finding must however be tempered by the fact that the more horizontal and more clinically relevant horizontal measures of mandibular growth (e.g. Pancherz analysis or pitchfork analysis) showed no such enhancement, even in that age group. This difference between the effect on overall mandibular length Co–Gn and the effect on the anterior component of mandibular growth is repeatedly found in the many excellent studies by Pancherz and co-workers on the Herbst appliance[7]. This fascinating paper revealed, in excellently clear graphs, that in the long term the *antero-posterior* change in pogonion was actually *less* with a Herbst appliance than in Bolton study patients matched for age and sex, although the *vertical* chin growth was slightly greater in the patients treated with the Herbst appliance. In other words, patients treated with the Herbst appliance actually ended up with a chin which was more posteriorly placed than that of the untreated controls. This disappointing aspect is understandably less frequently emphasised by those who have worked hard to obtain and subsequently publish and present these results at meetings.

A general message that we should take from this example is that the actual measurements made are an aspect of the research method that should be considered without just skipping over to the summary findings.

Another potential pitfall when interpreting research is the tendency to express results in an inappropriate format for clinical interpretation. For example, one good, recent and representative study can be correctly quoted as having found that of the changes compared to controls produced by the Herbst appliance combined with full fixed appliance, 40% were skeletal, which sounds substantial[8]. The more helpful description of the same data for a clinician considering adopting this technique is that the average overjet reduction was only 2.8 mm and that 40% (1.1 mm) of that was skeletal. Furthermore, the mandible moved anteriorly *less* in the treated group and all of the skeletal change that remained at the end of treatment was due to maxillary restraint as measured at A point.

However, not all the messages from research about the effect of functional appliances on growth are negative. The study by Hägg and co-workers investigated the possibility of restraining vertical maxillary growth with high-pull headgear and hence a conversion of the enhanced mandibular growth to a more anterior direction[9]. They did indeed find an anterior mandibular enhancement with this technique. Clinicians must however look at the useful but modest size of this enhancement and ask themselves if they wish to add headgear to their appliances to try to achieve this. This redirection of growth remains a potentially substantial improvement in the effects of functional appliances if it can become less dependent on patient cooperation.

A further factor to weigh in our interpretation of research in relation to the age of functional appliance patients is the clear evidence from several good studies that patients who start treatment beyond the age of 12.5 years are much less likely to complete it than those who start at a younger age. In the study by Banks et al., the difference was threefold[10]. In the quest to apply research to excellence in clinical practice, that is a large factor to weigh against the chance of greater favourable growth at 13–14 years of age in boys. Those who advocate the use of cervical spine maturation as a means of identifying those who have reached maximum potential growth should also appreciate and mention the relatively poor reproducibility of this method[11].

Clinicians should also guard against accepting at face value the adjectives used in papers to characterise results. For example, one paper studying the effects of the Herbst appliance says "the mandible underwent a remarkable forward repositioning"[12]. In fact, the angle SNB increased by an average of 0.25±0.67°. Perhaps editors should give more scrutiny to the use of adjectives in submitted articles, but readers always need to look at the figures behind the adjectives.

So, in the journey from evidence to clinical excellence, the thoughtful clinician should probably currently conclude that it is unlikely but not impossible that significant changes in jaw growth can result from the use of functional appliances. It is also well appreciated that the jaw growth that accompanies functional appliance therapy is highly variable. At present, no useful indicator of a favourable growth response has been identified. This conclusion does not, however, stop functional appliances from being highly effective correctors of Class II dental relationships.

SUCCESS RATE

This is also a crucial factor for the clinician considering the use of functional appliances. Although success rates have been studied and reported, this aspect is significantly underemphasised in many papers. Most functionals are removable and therefore require patient cooperation. Rates of success for twin block appliances vary but are



Figure 1: A twin block functional appliance. Studies support the view that compliance is on average better than with one-piece removable functionals, but still a factor of clinical significance. Details of the design can easily and usefully be modified to suit varying situations and the effects of some of these variations have been formally and informatively investigated.

frequently unacceptably high, even in experienced and skilful hands *(Fig. 1)*. So what is the best evidence concerning success rates? This partly depends upon how success is defined. A study on twin blocks that I co-authored found a failure rate of 9% if overjet reduction to less than 6 mm was the definition of success, but this rose to 17% if an overjet less than 4 mm was the chosen target[13]. Similarly, another study measured the rate of success of full correction of the molar relationship with the Bionator[14]. If 100% molar relationship correction was the criterion, this was only achieved in 42%. If <1/4 unit Class 2 was considered a success, the success rates went up to 83%. One RCT of twin blocks, of which I was a co-author, had a failure rate of 16% for younger patients, but a disappointingly high 30% rate of failure for patients averaging 12 years at the start of treatment who were treated by experienced and expert users of this appliance[3]. One caveat is that this 30% was in fact the rate of failure to collect all the required post-treatment records and this was probably a little higher than the actual failure to achieve a corrected occlusion, but a surprising and disappointing percentage nevertheless. Clinicians clearly need to look closely at the chosen definition of success when interpreting the headline figures. The 25% failure rate with twin blocks reported in the study by Banks et al. is probably representative of an average clinical expectation[10]. The lowest reported rates are around 15%[2,15]. These figures are likely to be robust and to reflect the range of success in a real-life situation in the hands of capable clinicians.

So, how many clinicians tell their patients the message from the evidence, namely that between 1 in 6 and 1 in 3 of them will not succeed with the appliance they are being prescribed? Do the specific effects of such an appliance justify such a failure rate clinically or financially? *Figure 2* shows a case where non-cooperation with a functional required extractions and yet a good result was achieved



Figure 2: This patient failed to wear her Dynamax two-part functional appliance in spite of no problems with the appliance and my best efforts at encouragement and persuasion. She was successfully and rapidly treated with self-ligating brackets, extraction of upper first premolars and Class II elastics.

© 2014 SIDO

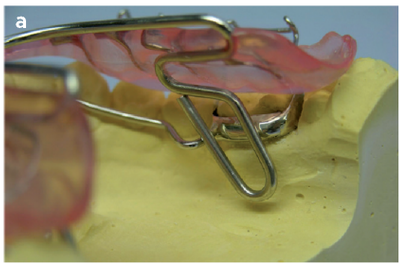



Figure 3: The Dynamax appliance can be very effective, but an RCT supported a common view from clinical experience that the breakage rate of the hangers is unexpectedly and unacceptably high in spite of considerable efforts to improve the design. An individual presented case is therefore not representative of the success of an appliance. Further innovation with this appliance may yet produce a robust design.

in 15 months with self-ligating fixed appliances and Class II elastics. Should we treat more cases in this way from the outset when functional appliances as currently used give only modest, short-term improvement in skeletal pattern and are not successful in correcting the dental relationships in a significant percentage of cases? My view is that functional appliances are still preferable in many cases because they reduce the need for extractions of healthy teeth and they give a slight skeletal improvement. Also, in patients with suboptimal oral hygiene, a removable functional can greatly reduce or even eliminate the duration of fixed appliance treatment. Some appliances have been promoted by their designer with understandable enthusiasm but have been found to be unacceptably fragile in the hands of experienced and skilful clinicians. I have had some very good results with the Dynamax appliance *(Fig. 3)* but I abandoned it because of excessive breakage and indeed an RCT involving this appliance[16] was discontinued on these grounds.

Fixed functional appliances offer the promise of 100% cooperation and success, yet the published studies show this is not the case. One paper from a unit extremely experienced with and enthusiastic about Herbst appliances found an extremely high rate of breakage with the banded Herbst appliance and of de-cementation of splinted Herbst appliances[17]. More recent fixed functional designs such as the Advansync *(Fig. 4)* and MARA appliances[18] show better success rates and greater practicability and efficiency, but the evidence is as yet limited and the jury is still out on the actual success rate with such appliances. This is an excellent example where simple but robust clinical audit can provide speedy and reliable information which helps the clinician much more rapidly and inexpensively than an RCT.

CONCLUSIONS

Nobody is 100% objective when interpreting research. Developers of appliances and techniques are naturally enthusiastic about their baby and have spectacles with a hue tending to the rosy end of the spectrum. That is human nature and we should always be grateful for their energy and initiative and persistence in developing new tools which can then be tried and tested by others and which may move us out of our naturally conservative habits to better clinical practice. It is even more understandable that manufacturers should try to see, select and publicise the more optimistic claims about their products. They have a clear financial interest, but we should also welcome their efforts to develop better appliances which will benefit patients. Perhaps less obviously, many researchers have financial and emotional drivers. A substantial and entirely understandable outcome for researchers (including myself) is to add to their pile of publications. Also, academics need these days to add to their grant income total. These are a quantifiable outcome measure of their work and they can be forgiven for not emphasising the limitations of the study which was so hard to obtain funding for and to carry out. RCTs rightly have an inherent street credibility which attracts money and authority for the authors' views on the clinical implications of their results, but each study is not inherently the authoritative and last word on a given topic, especially in a time of swiftly changing clinical practice in that field. So everyone potentially has an axe to grind. Nobody is completely immune from subjectivity and bias. Everyone has a large or small element of the football team supporter in their makeup. The challenge for thoughtful and conscientious clinicians is to examine all claims and conclusions in that light and to pick their way through the methods and the results to the currently most likely truth, even if that indicates a change of their views or their current clinical methods with which they are comfortable and have become adept. With the torrent of research, publications and conference presentations, this is not an easy task, but it is stimulating and rewarding. It is strongly in the best interest of our patients that we acknowledge the need for and strive to extract the best message from the evidence to help us towards clinical excellence. Hopefully this article and indeed this new journal is a help and a part of that continuous journey.



Figure 4.1: Treatment started at 11 years of age with an Advansync fixed functional appliance.





Figure 4.2: The day of placement of the appliance. Early levelling of lower curve of Spee and lower arch alignment were important in this case. The well-aligned upper arch can wait a visit or two.



Figure 4.3: Third visit. Upper brackets placed. The pistons are detached from the lower bands to test the Class II correction, which is approximately 2/3 achieved. Appliance then advanced to edge-to-edge incisor relationship.

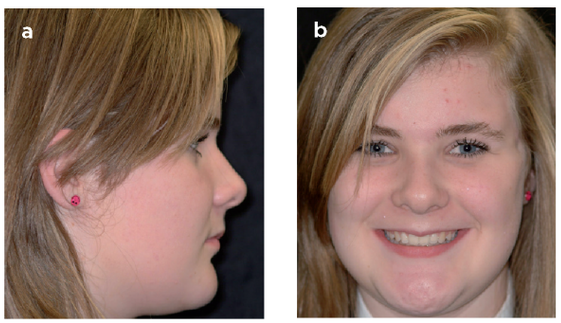

Figure 4.4: End of 14 months of active treatment with an Advansync appliance. Efficient Class II correction. Pleasing profile, although only the average 1° increase in angle SNB was achieved.



© 2014 SIDO

REFERENCE LIST

1. Dolce C, McGorray SP, Brazeau L, King GJ, Wheeler TT. Timing of Class II treatment: skeletal changes comparing 1-phase and 2-phase treatment. *Am J Orthod Dentofacial Orthop* 2007;**132**:481–489.
2. O'Brien K, Wright J, Conboy F, Sanjie Y, Mandall N, Chadwick S et al. The effectiveness of early treatment for Class II malocclusion with the Twin Block appliances: a multicentre randomized controlled trial. Part 1: dental and skeletal effects. *Am J Orthod Dentofacial Orthop* 2003;**124**:234–243.
3. O'Brien K, Wright J, Conboy F, Appelbe P, Davies L, Connolly I et al. Early treatment for Class II Division 1 malocclusion with the Twin-block appliance: a multi-center, randomized, controlled trial. *Am J Orthod Dentofacial Orthop* 2009;**135**:573–579.
4. O'Brien K, Macfarlane T, Wright J, Conboy F, Appelbe P, Birnie D et al. Early treatment for Class II malocclusion and perceived improvements in facial profile. *Am J Orthod Dentofacial Orthop* 2009;**135**:580–585.
5. Marsico E, Gatto E, Burrascano M, Matarese G, Cordasco G. Effectiveness of orthodontic treatment with functional appliances on mandibular growth in the short term. *Am J Orthod Dentofacial Orthop* 2011;**139**:24–36.
6. Cozza P, Baccetti T, Franchi L, De Toffol L, McNamara J. Mandibular changes produced by functional appliances in Class II malocclusion: a systematic review. *Am J Orthod Dentofacial Orthop* 2006;**129**:599.
7. Pancherz H, Ruf S, Kohlhas P. "Effective condylar growth" and chin position changes in Herbst treatment: a cephalometric roentgenographic long-term study. *Am J Orthod Dentofacial Orthop* 1998;**114**:437–446.
8. Wigal TG, Dischinger T, Martin C, Razmus T, Gunel E, Ngan P. Stability of Class II treatment with an edgewise crowned Herbst appliance in the early mixed dentition: skeletal and dental changes. *Am J Orthod Dentofacial Orthop* 2011;**140**:210–223.
9. Hägg U, Rabie A, Bendeus M, Wong RKW, Wey MC, Du X, et al. Condylar growth and mandibular positioning with stepwise vs maximum advancement. *Am J Orthod Dentofacial Orthop* 2008;**134**:525–536.
10. Banks P, Wright J, O'Brien K. Incremental versus maximum bite advancement during twin-block therapy: a randomised controlled clinical trial. *Am J Orthod Dentofacial Orthop* 2004;**126**:583–588.
11. Nestman TS, Marshall SD, Qian F, Holton N, Franciscus RG, Southard TE. Cervical vertebrae maturation method morphologic criteria: poor reproducibility. *Am J Orthod Dentofacial Orthop* 2011;**140**:182–188.
12. Manfredi C, Cimino R, Trani A, Pancherz H. Skeletal changes of Herbst appliance therapy investigated with more conventional cephalometrics and European norms. *Angle Orthod* 2001;**71**:170–176.
13. Harradine N, Gale D. The effects of torque control spurs in twin block appliances. *Clin Orthod Res* 2000;**3**:202–210.
14. Wheeler TT, Mc Gorry SP, Dolce C, Taylor MG, King CG. Effectiveness of early treatment of class II malocclusion. *Am J Orthod Dentofacial Orthop* 2002;**121**:9–17.
15. Morris DO, Illing HM, Lee RT. A prospective evaluation of Bass, Bionator and Twin Block appliances. Part I: The soft tissues. *Eur J Orthod* 1998;**20**:501–516.
16. Thiruvenkatachari B, Sandler J, Murray A, Walsh T, O'Brien K. Comparison of Twin-block and Dynamax appliances for the treatment of Class II malocclusion in adolescents: a randomized controlled trial. *Am J Orthod Dentofacial Orthop* 2010;**138**:144.e1–144.e9.
17. Hägg U, Tse EL, Rabie AB, Robinson W. A comparison of splinted and banded Herbst appliances: treatment changes and complications. *Aust Orthod J* 2002;**18**:76–81.
18. Al-Jewair TS, Preston CB, Moll EM, Dischinger T. A comparison of the MARA and the AdvanSync functional appliances in the treatment of Class II malocclusion. *Angle Orthod* 2012;**82**:907–914.

CLINICAL ARTICLE

Vertical Control of Second Molars in Fixed Appliance Treatment



*Stefano Troiani**

Private practice of Orthodontics, Siegen, Germany



Markus Gudde

Private practice of Orthodontics, Siegen, Germany

*Correspondence:
In Balance Kieferorthopädie •
Am Bahnhof, 11 • 57072 Siegen • Germany
e-mail: stefanotroiani@hotmail.com

Article history
Received: 16/07/2013
Accepted: 24/07/2013

"Posterior precontacts are the most common cause of insufficient overbite during orthodontic fixed appliance treatment. It is therefore very important to learn to identify such problems and address them with a proper biomechanical system"

Abstract

OBJECTIVES. A proper amount of overbite is necessary to obtain a sufficient disclosure of posterior segments during mandibular excursions. Increase of overbite during orthodontic fixed appliance treatment is often achieved by using anterior vertical elastics. Such a procedure does however, involve risks related to the increased incidence of root resorption and to potential condylar distraction. The authors, are moreover of the opinion that the use of anterior vertical elastics simply often fails to address the problem at its origin. A careful analysis of occlusion reveals that in most instances the lack of adequate overbite is caused by presence of posterior precontacts. Obtaining a sufficient overbite and eliminating posterior precontacts can therefore in most cases be achieved by controlling the vertical dimension at level of second molars.

MATERIALS AND METHODS. The present article examines five possible causes of posterior precontacts at level of second molars and subsequent bite opening during orthodontic fixed appliance treatment and suggests several possible biomechanical solutions. A case in which some of these solutions were used is presented as example.

CONCLUSIONS. Posterior precontacts are the most common cause of insufficient overbite during orthodontic fixed appliance treatment. It is therefore very important to learn to identify such problems and address them with a proper biomechanical system.

Keywords
Precontacts, open bite, vertical control

© 2014 SIDO

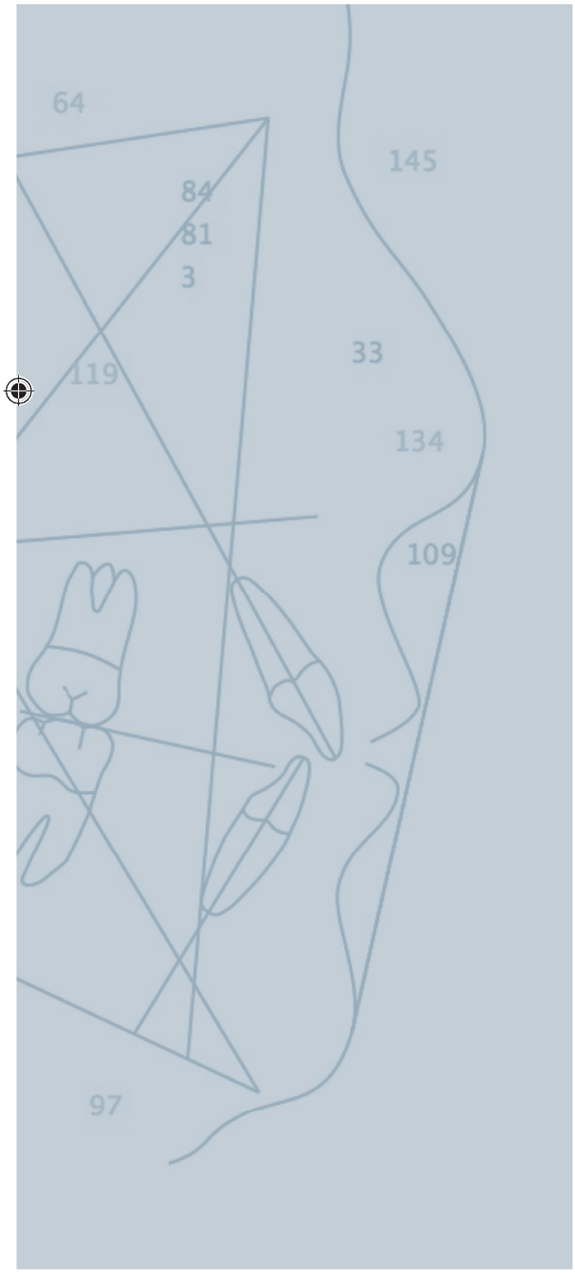

INTRODUCTION

One of the main occlusal goals of an orthodontic treatment is to obtain a proper amount of overbite.

This is commonly quantified in 2 mm but according to some authors 3 to 4 mm would be more optimal[1], in order to facilitate disclosure of molars during mandibular protrusion and disclosure of the non-working side during mandibular lateral excursion[2].

Several authors have shown the relationship between the presence of posterior precontacts during protrusion and/or lateral movement of the mandible and altered muscular function[3-9], although there is no consensus about the relationship between occlusion and temporomandibular dysfunction[10-14].

The cause of a lack of adequate overbite can be skeletal, articular or occlusal, or an interaction of two or more of the above.

It is beyond the purpose of this article to evaluate the treatment of skeletal or dentoalveolar open bite, the authors have chosen to analyze some of the occlusal aspects of bite opening, focusing on the mechanics and the tools to use for vertical control during treatment with full fixed appliance.

The most common tool in orthodontics to increase the amount of overbite is the use of vertical elastics. However, such tool presents three main shortfalls: first, the use of elastics tends to produce jiggling and therefore potentially increase the risk for root resorption[15]. Secondly, the lack of overbite is most often caused by the presence of posterior precontacts and the use of anterior vertical elastics simply fails to address the problem at its origin. Moreover, the presence of posterior precontacts is often overlooked, given that 85 % of the errors found in board cases presented at the ABO were found to be at the level of second molars[16]. Third, the use of vertical elastics can potentially, in presence of a posterior fulcrum, cause a distraction of the condyle, leading to a lack of stability of the achieved results, due to the compounding of condylar relapse and dental relapse.

In this article, the authors will analyze 5 different possible causes of posterior precontacts and consequently lack of adequate overbite, suggesting possible clinical solutions for each case *(Fig. 1)*.

The authors especially wish to emphasize that it is not in the authors intention to provide a "cookbook" solution, being the primary interest to focus on recognizing the origin of occlusal precontacts, to which many solution can be applied.

A clinical case will then be presented in which different tools had to be used to achieve an adequate overbite.

© 2014 SIDO

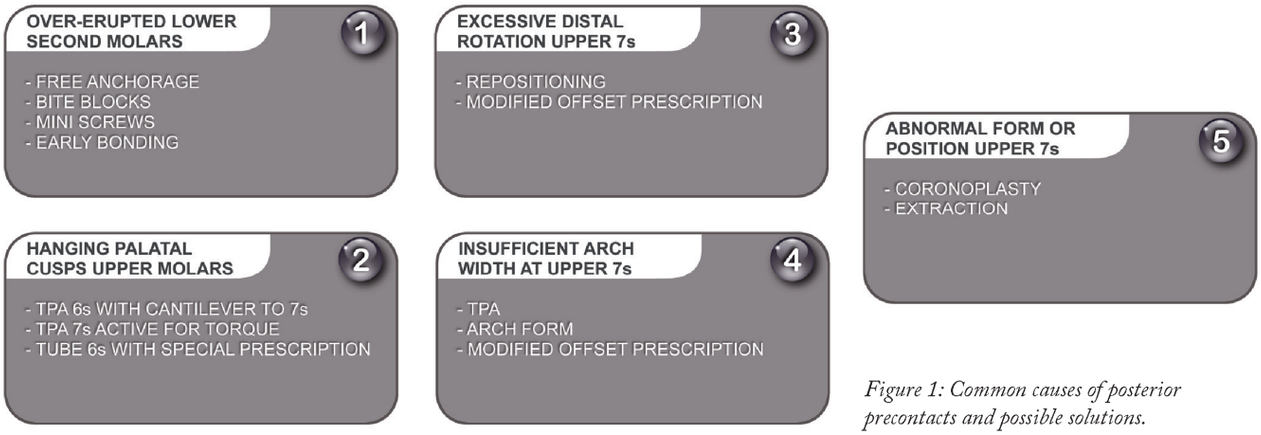

Figure 1: Common causes of posterior precontacts and possible solutions.

1. OVER-ERUPTED LOWER SECOND MOLARS

A possible source of posterior precontact is over-eruption of lower second molars.

The most common cause of such overeruption is a delayed eruption of the upper second molars which, especially in presence of distal molar occlusion, will leave the lower second molars without an antagonist and therefore free to erupt above the occlusal plane.

Indiscriminate leveling of such over-erupted second molars with a straight wire coming from the first molars leads to the risk of generating unwanted side effects due to unwanted moments and forces depending on the reciprocal angulation of the slot of the first and second brackets.

Although it is not possible for the clinician to calculate the moment of forces generated in a statically indeterminate system[17], a description and schematization of the force system generated by the insertion of a wire in the slot of 2 brackets has been done by Burstone and Koenig[18]. This situation can be reasonably compared to the one occurring between second and first molar as we level an over-erupted second molar (although of course the archwire is inserted in the full arch, making it impossible to calculate all force and moments generated[19]).

According to this model, the insertion of a straight wire in an over-erupted second molar, will generate a force system typical of a I-III geometry of Burstone-Koenig, which will lead to over-eruption of the first molar and steepening of the occlusal plane, due also to the fact that the eruptive force on the first molar tend to be expressed more promptly than an intrusive force on the second molar *(Fig. 2)*.

In patients in whom the treatment plan includes extraction of premolars, a possible way to avoid the described side effects is to benefit from the concept of "free anchorage"[20] and use the premolars which are to be extracted to level the second molars *(Fig. 3)*. It is important to underline how the premolars to be extracted are to be used for leveling the over-erupted second molars but the decision to extract premolars should be independent from this.

In patients in which no extractions are planned, the use is suggested of bite blocks on the first molar, which prevent the expression of the unwanted extrusive force while the second molars are leveled.

The bite blocks can be fixed or removable: the fixed form has the advantage of not relying on patient cooperation but may create a fulcrum with possible effect of condylar distraction.

The removable bite block *(Fig. 4)* should be built in articulator to obtain stable occlusal contacts in centric relation, minimizing the negative effects on the articulation.



Figure 2: Force system generated by a straight wire inserted between first and second molars when second molars are overerupted.

© 2014 SIDO



Figure 3: Use of premolars which are going to be extracted as free anchorage to level overerupted second molars.



Figure 4: Removable bite block.

2. HANGING PALATAL CUSPS OF UPPER MOLARS

A second source of posterior prematurities is the hanging of the palatal cusps of upper first or, more often, second molars.

The cause of the excessive vestibular crown torque of upper molars can be due to asynchronous eruption of antagonist in the lower arch, anatomy of the facial cortical plate of the maxilla, presence of wisdom teeth facial to the apex of the roots of the upper second molars.

A possible solution to this problem is the use of attachments on the upper second molars with increased value of lingual crown torque, together with the use of passive transpalatal arches on the first molars to limit the side effects. This technique presents two main shortcomings: first, it implies that the second and first molar have to be leveled before correcting the torque, where it would be best to correct the torque before leveling, since the flaring of the second molars means that the attachments on the second molars will be placed on a different vertical level (more gingival) respect to the one on the first molar and therefore leveling will give steepening of the occlusal plane and flaring of the first molars (due to the vertical intrusive force vestibular to the center of resistance of the molar). Second, the level of force delivered by the distal end of the tube is rather reduced and very often not sufficient to correct the torque of molars.

A second possible way of correcting



Figure 5: Passive transpalatal arch on the first molars with two soldered cantilevers activated for intrusion and ligated to the lingual face of second molars.

the torque of second molars is to use a passive transpalatal arch on the first molars with two soldered cantilevers activated for intrusion and ligated to the lingual face of second molars *(Fig. 5)*. The problem with this approach is the fact that the palatal vault is normally concave with the lateral wall not perfectly vertical but at an angle, therefore the use of the above described cantilever will also give on the second molars an unwanted horizontal force directed lingually and tending to reduce the transversal arch diameter at level of the second molars.

The biomechanically most sound solution appears to be the insertion of a transpalatal arch activated for reciprocal torque at the level of the second molars, generating a geometry V to VI[18]. The drawback of this solution is the patient's comfort, since the presence of a transpalatal arch at the level of the second molars is not always tolerated (especially in case of patient with flat palate).

3. EXCESSIVE DISTAL ROTATION OF UPPER MOLARS

When analyzing the patients occlusion during the finishing stage of treatment, a very frequent finding will be the presence of a pre-contact on the disto-vestibular cusp of the upper second molars.

This is due to the additional distal rotation present in most bracket prescriptions.

Beside the obvious solution of adopting a prescription with a lesser degree of distal rotation built into the appliance at the level of upper molars, the tool which can be used to solve the situation is once again a transpalatal arch at the level of first and/or second molars.

4. INSUFFICIENT TRANSVERSAL UPPER ARCH WIDTH

The fourth problems is strictly connected to the above mentioned point. The marked amount of distal rotation is present in both first and second molar attachments. The



Figure 6: Patient M.R., extraoral pictures pre-treatment.

© 2014 SIDO

distal rotation of the first molar will tend to project lingually the distal end of the archwire and this will add to high distal rotation of the second molar itself, generating a reduction in transversal width. The correction can be done by expanding the archwire or by using a transpalatal arch (better as it will simultaneously work on the rotation).

5. ABNORMAL FORM OF UPPER SECOND MOLARS

The upper second molars are frequently of abnormal form.
Sometimes this anomaly will not permit to achieve a proper occlusion, and sometimes not even bonding of the second molars.
A solution to this problem may be negative coronoplastic or, when wisdom teeth are present, eventual extraction of the upper second molars.

CLINICAL CASE

The patient M.R came to our observation at age 13 years and 2 months with a primarily cosmetic complaint of generic nature.
The general anamnesis did not evidence relevant problems, nor did the clinical functional examination.
On the extraoral examination, lack of support was found of the upper and lower lip, together with the necessity to avoid retraction of the upper incisors *(Fig. 6)*.
Intraorally, there was a shallow overbite with open bite tendency, over-eruption of 37 47 and transversal incoordination with crossbite, even more accentuated when taken into account the presence of lingual tilting of the lower molars as dentoalveolar compensation *(Fig. 7)*.
There was no significant difference between CO and CR *(Fig. 8)*.
Radiographically, the cephalometric analysis revealed a normo to dolico-cephalic growth pattern and slightly increased proclination of the upper and lower incisors *(Fig. 9)*.

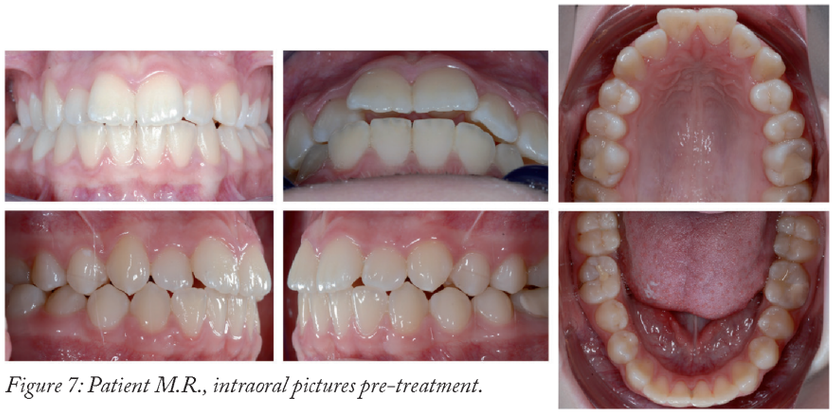

Figure 7: Patient M.R., intraoral pictures pre-treatment.

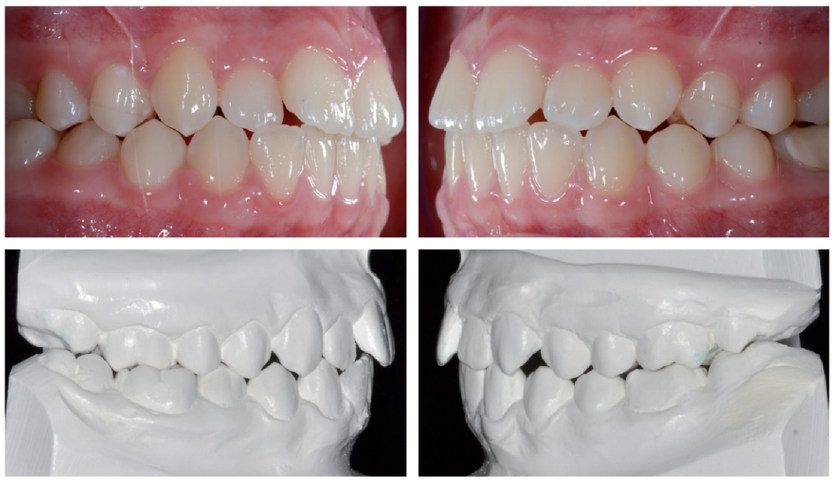

Figure 8: Patient M.R., articulator mounting in CR pictures, pre-treatment.

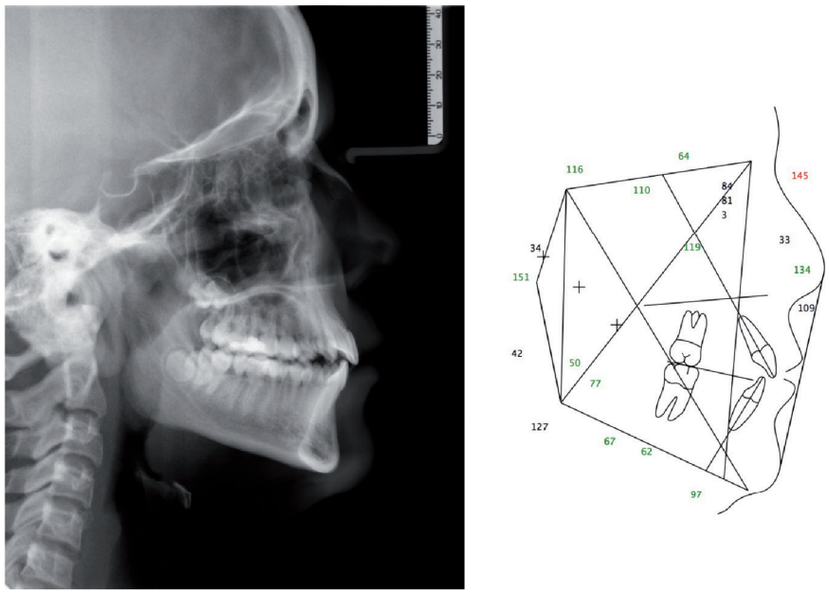

Figure 9: Patient M.R., pre-treatment lateral teleradiograph and cephalometric analysis according to Roth-Jarabak.



Figure 10: Patient M.R., orthopantogram pre-treatment.

The orthopantogram showed short, "bottle shaped" roots of the upper incisors *(Fig. 10)*. "Bottle shaped" roots are recognized as strong risk factor for root resorption during orthodontic treatment[21, 22].

The case presented therefore several challenges, *i.e.* the need to:

- improve (or at least not worsen) the definition of upper and lower lip;
- increase the vertical overbite, considering at the same time the absolute contraindication to the use of anterior vertical elastics due to the bottle-shaped short roots of upper incisors;
- increase the transversal dimension of the upper arch, while controlling at the same time the bite opening;
- level the overerupted 37 and 47 without further bite opening.

It was clear how the key to a successful treatment was the need for absolute vertical control.

The case began with leveling of the lower arch *(Fig. 11)*.

At the same time, the upper arch was expanded with a rapid maxillary expander with occlusal acrylic coverage. The choice of this appliance was taken being aware that the age of the patient was at the limit for this type of treatment. The appliance was built in articulator so to provide the maximal occlusion possible with the lower arch, so to counteract the steepening of the occlusal plane caused by the leveling of the over-erupted 37 and 47.

As a detail, a small acrylic extension was built so to prevent over-eruption of 17 and 27 while occluding on the other teeth of the posterior segment *(Fig. 12)*.

After the phase of expansion of the upper arch, a transpalatal arch was inserted as retention. During this phase, orthodontic mini-screws were inserted in the lower posterior segments and coupled with the use of a lower lingual arch,

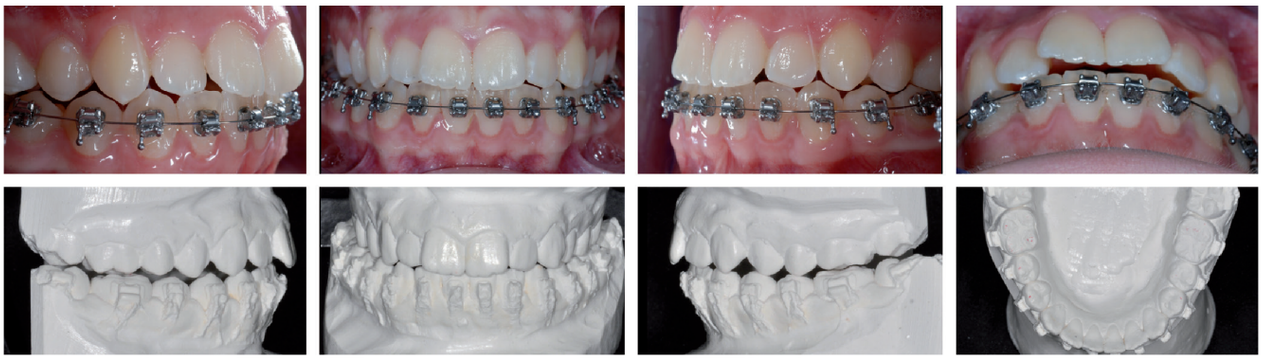

Figure 11: Patient M.R., initial levelling lower arch.

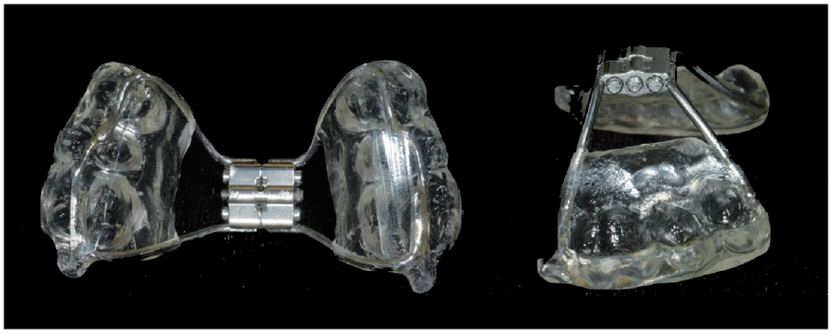

Figure 12: Patient M.R., rapid maxillary expander with occlusal acrylic coverage.

© 2014 SIDO

in order to control the side-effects generated by leveling of 27 and 37 in progressing thicker rectangular NiTi wires, once the bite-block effect of the hyrax occlusal acrylic coverage was no longer present *(Fig. 13)*.
Leveling was then begun of the upper arch and a first bracket repositioning was planned after intermediate impressions taking *(Fig. 14)*.
Transpalatal arches were used on both first and second upper molars in order to control the torque and avoid posterior pre-contacts *(Fig. 15)*.
A final intermediate impression was taken and mounted in articulator, evidencing the presence of posterior precontact on the disto-vestibular



Figure 13: Patient M.R., levelling both arches, orthodontic screws in lower arch.

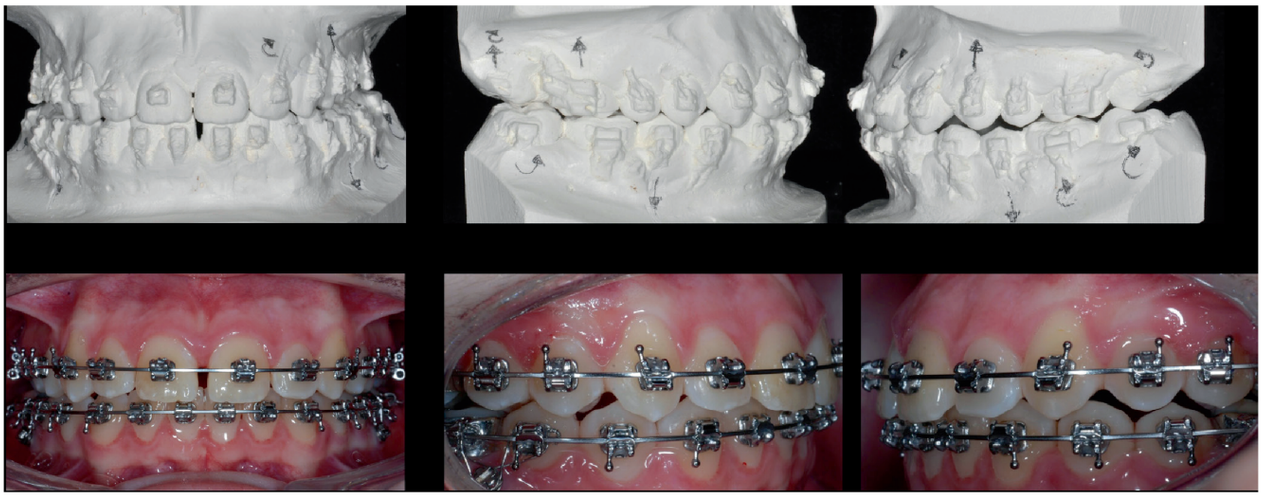

Figure 14: Patient M.R., first systematic bracket repositioning.

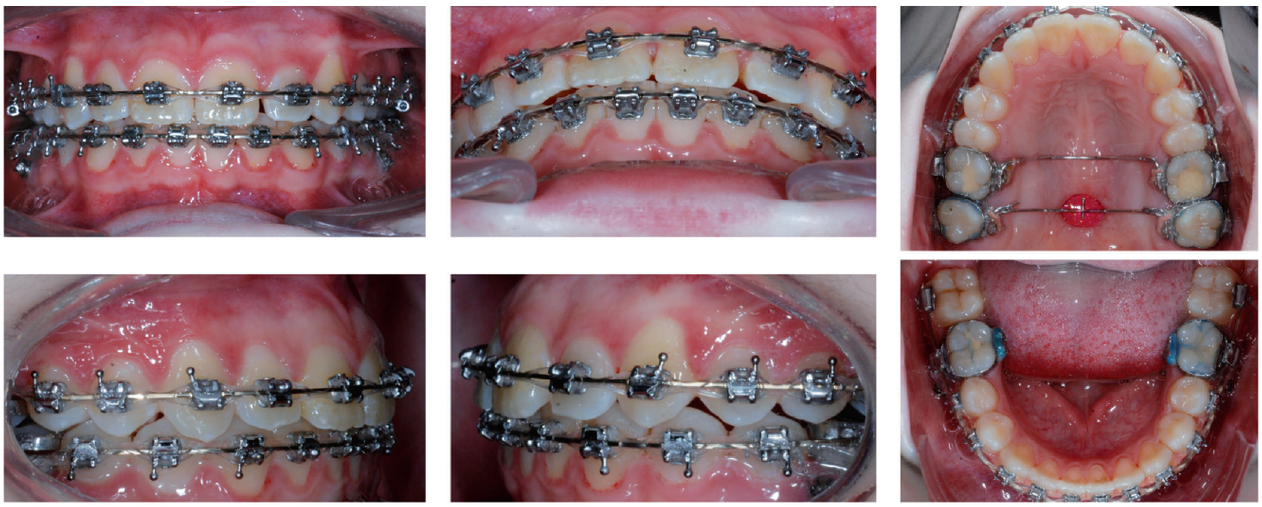

Figure 15: Patient M.R., Ss archwires and transpalatal arches to control molar torque.

© 2014 SIDO

cusp of the upper second molars, which was corrected by introducing slight expansion and distal rotation on the transpalatal arch on the second molars *(Fig. 16)*.
The final intraoral result showed the achievement of a solid neutral occlusion with a sufficient amount of vertical overbite and a nearly complete coincidence of centric relation and centric occlusion *(Fig. 17)*.
Extraorally, there were no significant changes *(Fig. 18)*.
The final orthopantogram evidenced slight blunting of the apex of the upper incisors roots; this took place despite avoiding the use of vertical elastics, but it is likely an unavoidable effect in presence of bottle-shaped roots *(Fig. 19)*.
Superimposition on the cranial base stable structures showed linear vertical growth with no significant changes in incisal position and torque *(Fig. 20)*.
Pictures taken at the end of retention *(Fig. 21)* and 1 year after the end of retention *(Fig. 22)* showed a good stability of the result, thanks also to the mutual support provided by the upper and lower incisors in presence of adequate overbite and optimal intercuspidation.

CONCLUSIONS

One of the major factors for an optimal function and a good stability



Figure 16: Patient M.R., final systematic bracket repositioning, impressions mounted in articulator.

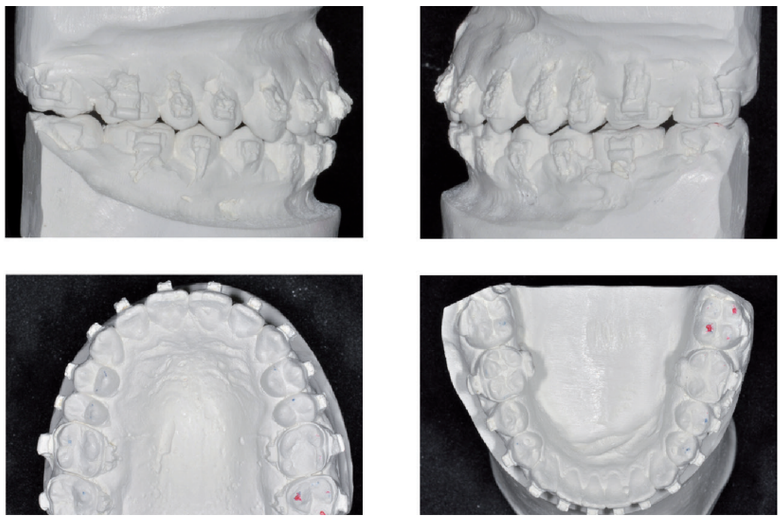



Figure 17: Patient M.R., occlusal final result.



Figure 18: Patient M.R., extraoral final result.

© 2014 SIDO

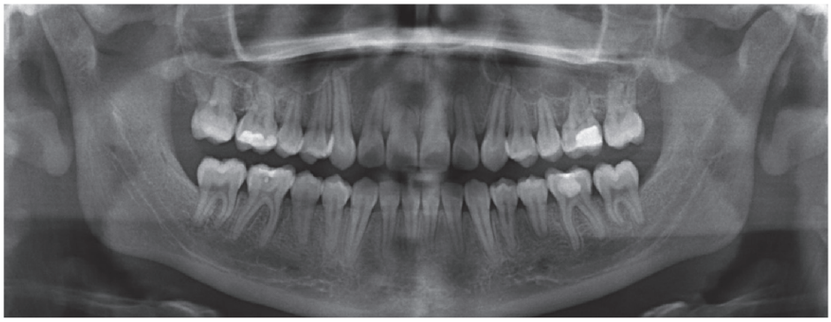

Figure 19: Patient M.R., orthopantogram final.

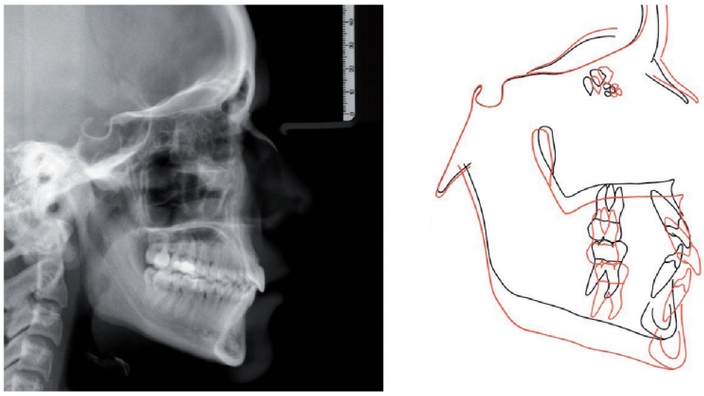

Figure 20: Patient M.R., final lateral teleradiography and superimposition initial to final teleradiography (superimposition on cranial base stable structures).

of result is the achievement of a proper amount of vertical overbite.
This should be achieved trough the elimination of posterior occlusal interferences rather then the use of anterior vertical elastics.
It may be said that consideration must be given to the occlusion of our patients from the posterior to the anterior and not vice versa.
Fundamental in this sense is the control of upper and lower molars.
Primary emphasis has to be given to tools for diagnosis of posterior problems.
A proper biomechanics will be indispensable but can come only after the identification of a problem, since it has to be objective oriented.



Figure 21: Patient M.R., occlusal result at end of retention (2 years).



Figure 22: Patient M.R., occlusal result 1 year after end of retention.

© 2014 SIDO

REFERENCE LIST

1. Lee RL. Esthetics and its relationship to function. In: Rufenacht C. Ed. Fundamental of Esthetics. Carol Stream: Quintessence; 1990:149-150.
2. Okeson JP. Management of Temporomandibular Disorders and Occlusion. 5th ed. St Louis: CV Mosby; 2003:109-126.
3. Shiau YY, Syu JZ. Effect of working side interferences on mandibular movement in bruxers and non-bruxers. *J Oral Rehabil* 1995;**22:**145-51.
4. Tunjan L, Schneider HG. Mode and frequency of artificially produced occlusal interferences. *Stomatol DDR* 1989;**39:**95-99.
5. Kloprogge MJ, Van Griethuysen AM. Disturbances in the contraction and coordination pattern of the masticatory muscles due to dental restorantions. *J Oral Rehab* 1976;**3:**207-216.
6. Christensen LV, Rassouli NM. Experimental occlusal interferences. Part I: a review. *J Oral Rehabil* 1995;**22:**515-520.
7. Belser UC, Hannam AG. The influcence of altered working-side occlusal guidance on masticatory muscles and related jaw movement. *J Prosthetic Dent* 1985;**53:**406-413.
8. Vallon D, Ekberg EC, Nilner M, Kopp S. Short-term effect of occlusal adjustment on craniomandibular disorders including headaches. *Acta Odontol Scand* 1991;**49:**89-96.
9. Watanabe EK, Yatani H, Kuboki T, Matsuka Y, Terada S, Orsini MG, et al. The relationship of signs and symptoms of temporomandibular disorders and bilateral occlusal contact patterns during lateral excursions. *J Oral Rehabil* 1998;**25:**409-415.
10. Wassell RW. Do occlusal factors play a part in temporomandibular dysfunction? *J Dent* 1989;**17:**101-110.
11. Okeson JP. Management of Temporomandibular Disorders and Occlusion. 5th ed. St Louis: CV Mosby; 2003.
12. Henrikson T, Nilner M. Temporomandibular disorders, occlusion and orthodontic treatment. *J Orthod* 2003;**30:**129-137.
13. McNamara JA, Seligman DA, Okeson JP. Occlusion, orthodontic treatment and temporomandibular disorders: a review. *J Orofac Pain* 1995;**9:**73-90.
14. Pahakala R, Qvarnström M. Can temporomandibular dysfunction signs be predicted by early morphological or functional variables? *Eur J Orthod* 2004;**26:**367-373.
15. Levander E, Malmgren O, Stenback K. Apical root resorption during orthodontic treatment of patients with multiple aplasia: a study of maxillary incisors. *Eur J Orthod* 1998;**20**:427-434.
16. The American Board of Orthodontics. Grading system for dental casts and panoramic radiographs. Revised June 2012.
17. Melsen B. Adult Orthodontics. Hobken: Wiley-Blackwell 2012:110-111.
18. Burstone CJ, Koenig HA. Force system from an ideal arch. *Am J Orthod* 1974;**65:**270-289.
19. Melsen B.: Adult Orthodontics. Hobken: Wiley-Blackwell 2012:112.
20. Melsen B. Dr. Birte Melsen on adult orthodontic treatment. Interview. *J Clin Orthod* 2006;**40:**703-716.
21. Sameshima G, Sinclair PM. Predicting and preventing root resorption: Part I. Diagnostic factors. *Am J Orhod* 2001;**119:**505-510.
22. Mirabella D, Årtun J. Risk factors for apical root resorption of maxillary anterior teeth in adult orthodontic patients. *Am J Orthod* 1995;**108:**48-55.

© 2014 SIDO

Upper and Lower Incisor Torque and Straight-Wire Appliance



Raffaele Spena

Private Practice in Orthodontics, Naples, Italy

Correspondence
Via dei Mille 13 • 80121 Naples • Italy
e-mail: rspen@tin.it

Article history
Received: 17/10/2013
Accepted: 10/01/2014

“How to increase flexibility and efficiency in reaching a better torque final position of the upper and lower anterior teeth when using straight-wire appliance”

Abstract

Biomechanical control of the torque of the upper and lower anterior teeth is critical in most treatments. Straight-wire appliances are designed to treat Class I and II malocclusions and overcorrections of the prescriptions are intended to help in Class I and Class II biomechanics. They are not designed for Class III malocclusions or Class III biomechanics and produce little control of severely proclined upper and lower incisors unless extremely valid anchorage is available and/or ample spaces are created in the arch. Rotation of 180° of an upper anterior straight-wire bracket is a common expedient frequently used by orthodontists to solve torquing needs. In this paper, rotation of the brackets of all four incisors during the initial stages of treatment to achieve the desired position and eventually overcorrect it, followed by their repositioning in the correct way to obtain final correct tip, torque and offset is described. Clinical and biomechanical situations are presented to show the advantages of such a simple stratagem.

Keywords
Straight-wire appliance, anterior torque, self-ligating brackets

© 2014 SIDO

INTRODUCTION

When, in 1972, L.F. Andrews published his article on the six keys to normal occlusion[1], the objectives of natural anatomical and functional dental treatment were described for the first time in the orthodontic literature.

In the 1970s, the first straight-wire appliance (SWA) was presented: brackets with a specific tip, torque and offset for each tooth of the upper and lower arch became available. The SWA was presented as an appliance that should allow obtaining Andrews' six keys. However, cases treated with the original SWA showed some problems at the end of treatment: lack of incisor torque, molar mesial rotation, upper molar buccal flaring, rotation in the extraction sites and unlevelled curve of Spee. The appliance was unable to overcome the biomechanical problems during the treatment of common orthodontic problems. Andrews developed several (12 different ones) prescription brackets, called translation or extraction brackets[2], in an attempt to solve these orthodontic problems. However, it was impractical to have so many different brackets with slight differences in the prescriptions to treat everyday cases.

In 1976, Roth[3] presented a SWA where selected overcorrected tip, torque and offset should have been effective in treating any malocclusion, accounting also for overcorrection, settling and solution for the common orthodontic biomechanical problems. Today, Roth's prescription brackets are still one of the most used SWAs.

A few years later, the MBT prescription[4] and many others were on the market. The common idea of all the SWAs has been to allow an optimal dental position and occlusion to be achieved and to help with the common problems encountered in moving teeth from a pathological position to the desired final position.

In the last 12 years, self-ligating brackets (SLBs) have acquired greater and greater popularity. The interactive SLBs allow great efficacy in expressing the torque (the most difficult information to obtain) built into the bracket. The last generation of thermal NiTi wires, used in combination with the interactive SLB, create a system that is highly effective in achieving tooth movement and final position in a very reliable way.

In this paper, we will refer to In-Ovation© SLBs with modified prescriptions *(Fig. 1)* but what will be described could be achieved with any pre-adjusted appliance.

LIMITS OF THE SWA

Every SWA, as any fixed and removable orthodontic system, has limitations in controlling the torque of the upper and lower anterior teeth. This problem may be partially overcome by the early expression of torque values during treatment with the use of square or rectangular thermal NiTi wires like the 0.020"x0.020" Bioforce© combined with active SLBs. Still, once working archwires such as 0.019"x0.025" stainless steel have been inserted, the anterior control may become critical when using intra- or intermaxillary forces.

The SWA appliances are all designed to treat Class I and II malocclusions and overcorrections are intended to help in Class I and Class II biomechanics. They are not designed for Class III malocclusions or Class III biomechanics. When treating Class III problems, one of the usual risks is ending up with flared upper incisors, lingually inclined lower incisors, shallow overjet and overbite. Often, it would be desirable to have buccal root torque on the upper incisors and lingual root torque on the lower incisors *(Figs. 2 and 3)*.

At the same time, severely proclined upper and lower incisors are biomechanically difficult to treat unless extremely valid anchorage control is available and/or ample spaces are created in the arch.

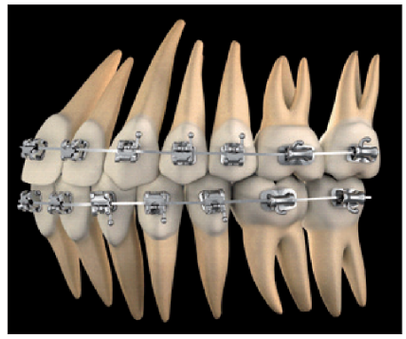

Figure 1: The In-Ovation© brackets and the new CCO prescriptions.
© Registered trademark of GAC International, Bohemia, NY; www.gacintl.com

ROTATION OF THE STRAIGHT WIRE ANTERIOR BRACKETS

Rotation of 180° of the upper anterior SWBs is a common expedient frequently used by orthodontists to solve torquing needs. This different positioning allows the torque prescription to be changed while keeping all the other values unaltered. When an upper lateral incisor is palatally displaced, for example, by rotating the bracket and inserting a rectangular wire, it is possible to properly move buccally both the crown and the root and, possibly, to overcorrect the final root positioning, thus increasing stability.

Even the most sophisticated machine (appliance) needs a thinking pilot (clinician) and has to have the flexibility to treat different orthodontic problems. The idea is that all four anterior brackets may be used in a conventional way or rotated 180° according to the torquing needs. This "unconventional positioning" can be done temporarily during the initial stages of treatment to achieve the desired position and eventually overcorrect it. In the final stage of detailing, brackets may be

© 2014 SIDO



Figures 2, 3: Undesired final result after Class III treatment. Class III biomechanics may need buccal root torque on upper incisors and lingual root torque on lower incisor



Figure 4: Adult patient with Class III malocclusion and dental and skeletal asymmetry.

repositioned in the traditional way to obtain the correct torque, tip and offset, as present in the SWA.

PROPOSAL FOR CLASS III MECHANICS

Class III malocclusions may present in a wide range of severity. Some may need surgery and some may be successfully treated with orthopaedic–orthodontic treatment. Class III mechanics requires exceptional control of the rotation of the occlusal plane and of the upper and lower anterior torque. In both the lower and the upper arch, all teeth must be included in the multibracket appliance and heavy stainless steel wires must be used in the working stage.

The initial position of the incisors and the width of the symphysis and the premaxilla on cone beam computed tomography (CBCT) scans should be carefully evaluated. This may influence the appropriate torquing needs and the consequent positioning of the anterior brackets. If the upper incisors are flared and the premaxilla is anteroposteriorly wide enough, it is recommended to position all four upper anterior brackets rotated 180° to have a buccal root torque. If the lower incisors are upright or lingually inclined, all four anterior brackets need to be rotated to produce a lingual root torque that will counteract their tendency to incline even more lingually under the Class III mechanics.

As said before, the brackets' rotated position may be kept as long as the Class III mechanics is needed. When the final stage of detailing is reached, the anterior brackets may be rebonded (rebonding is a common practice when using fixed appliances and, even more so, SWA) in the conventional way to obtain the desired final tooth position.

In a study conducted on the effective expression of torque when using active SLB, Gick et al. have shown how torque depends on the wire and slot dimension[5]. In a 0.022" slot, torque is expressed by 77% when using a 0.017"x0.025" wire, by 86% when using a 0.018"x0.025" wire and by 100% when using 0.019"x0.025" or greater wires. These differences may be considered to help decide how much torque expression is desired and to choose the appropriate wire to insert in the anterior bracket slots during Class III mechanics.

In *Figures 4–10*, a Class III malocclusion in an adult patient is shown. The patient's family refused the proposed combined orthodontic–surgical treatment. It was decided to treat the malocclusion only with orthodontics. At the beginning of treatment, both the upper and the lower incisors were proclined. It was decided to rotate only the upper incisors to produce a buccal root torque. The lower anterior brackets were bonded in a conventional way to produce a lingual root torque to achieve a more upright final position.

© 2014 SIDO



Figure 5 (a–i): Intraoral pictures of the initial malocclusion and the stages of the orthodontic treatment. The brackets on the anterior teeth have been bonded rotated 180°. Class III mechanics have been conducted on upper and lower 0.019"×0.025" stainless steel wires.



Figure 6: Patient at the end of treatment. The predominance of the chin as well as the asymmetry have been reduced



Figure 7: Intraoral pictures at the end of treatment. The Class III relationships have been solved and acceptable overjet and overbite have been achieved

© 2014 SIDO



Figure 8: Close-ups of the initial and final smile of the patient. Note the improved appearance of the upper and lower incisors

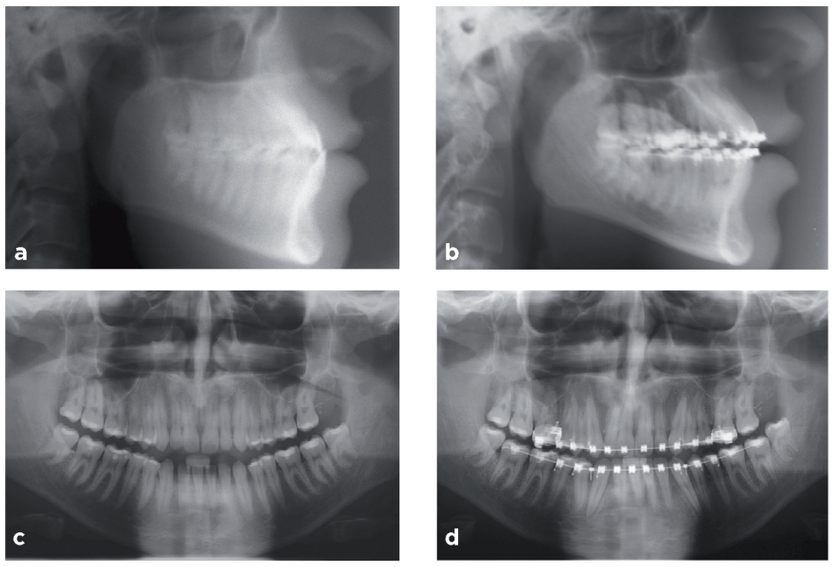

Figure 9 (a-d): Close-ups of the initial and final(before debonding) lateral cephalograms and panorex

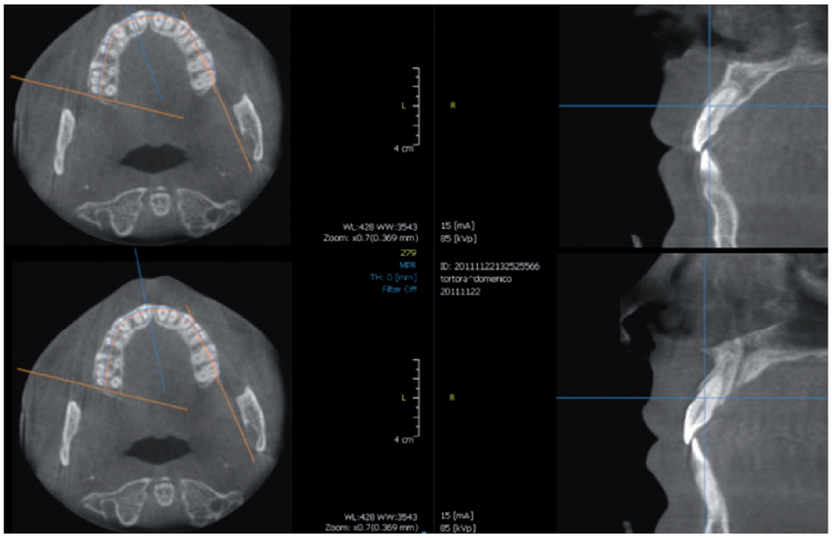

Figure 10: CBCT scans of the right upper central and lateral incisors at the end of treatment. Careful evaluation of the width of the premaxilla and the position of the roots allows to proper final positioning

© 2014 SIDO



Figure 11: Adolescent patient with Class III malocclusion and dental bimaxillary protrusion.

Figures 11–16 show the treatment and the end result in a growing patient with a bimaxillary dental protrusion and a Class III skeletal relationship.

PROPOSAL FOR PROCLINED INCISORS

Malocclusions with bimaxillary dental protrusion may need different solutions according to the aesthetic, functional and periodontal objectives. Extractions of premolars and maximum posterior anchorage may be needed for the most severe biprotrusions. In mild cases, minor



Figure 12 (a–l): Intraoral pictures of the initial malocclusion, the stages of the orthodontic treatment and the final result. The brackets on the anterior teeth have been bonded rotated 180°. Class III mechanics have been conducted on upper and lower 0.019"×0.025" stainless steel wires. Final settling with upper and lower 0.019"×0.

© 2014 SIDO

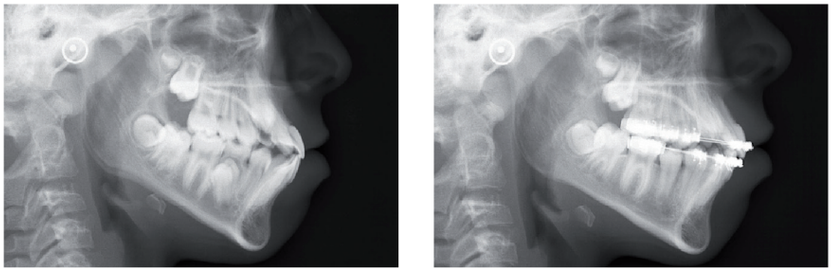

Figure 13: Close-ups of the initial and final (a few months before debonding) lateral cephalograms.



Figure 14: Patient at the end of treatment. The procumbency of the anterior teeth has been reduced without flattening the patient's beautiful profile.



Figure 15: Close-ups of the initial and final smile of the patient. Note the improved appearance of the upper and lower incisors.

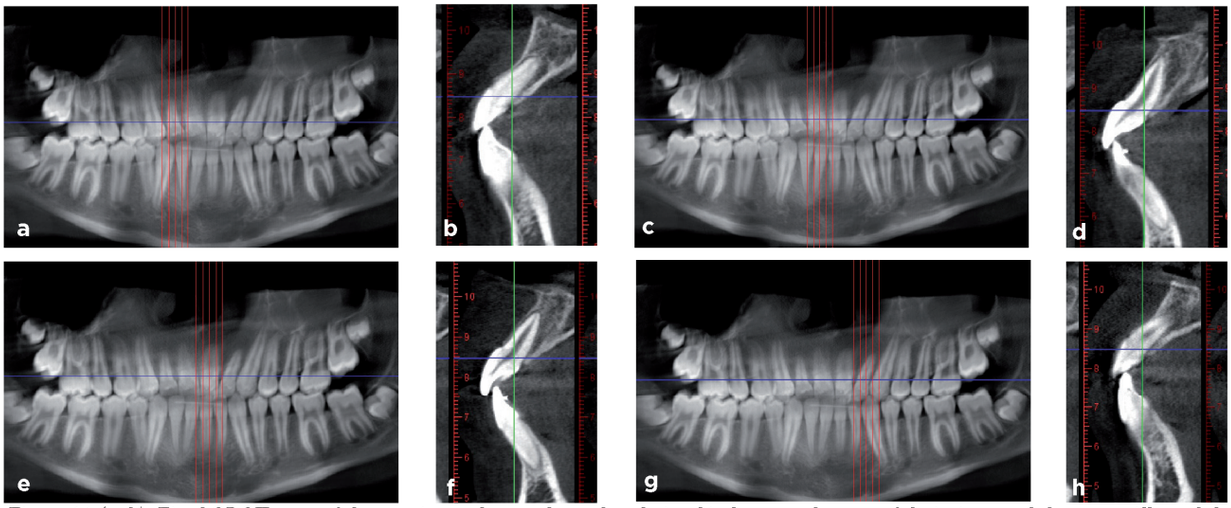

Figure 16 (a–h): Final CBCT scans of the anterior teeth to evaluate the relationship between the roots of the incisors and the premaxilla and the symphysis.

space gaining and proper torque of the upper and lower incisors may be indicated *(Fig. 17)*.
SWAs do not help in these situations. The new Complete Clinical Orthodontics (CCO)[6] prescriptions have –6° in the lower anterior teeth, which are more effective in obtaining the desired final upright position. In the upper arch, during the final part of the levelling phase, when square or rectangular thermal NiTi wires are used, and during the working stage of biomechanics with rectangular stainless steel wires, the anterior brackets may be rotated 180° to produce buccal root torque. Again, the width of the premaxilla on CBCT scans and of the initial



Figure 17: Mild upper and lower dental anterior protrusion may be solved by minor space gaining in the arches and buccal root torque on both the upper and lower incisors.





Figure 18: Patient with a dental bimaxillary protrusion at the beginning of treatment. The patient's objective was to reduce procumbency of the anterior teeth. Having already extracted all four third molars, the patient refused to have any further teeth extracted.



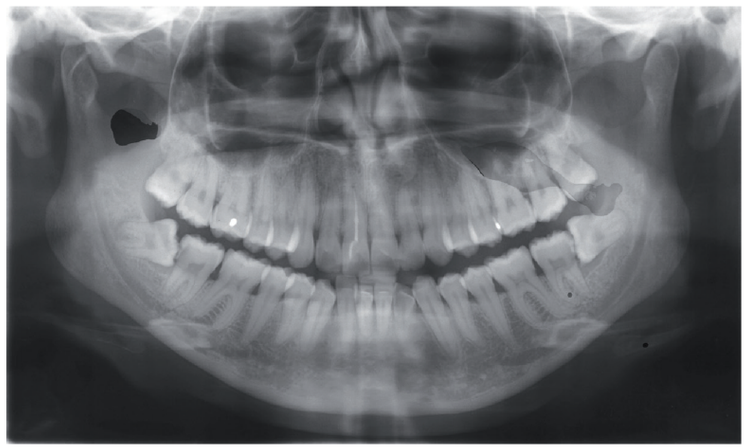

Figure 19: Initial lateral cephalogram and panorex. Note the procumbency of the anterior teeth and the four third molars that have been extracted before the beginning of the orthodontic treatment.

© 2014 SIDO



Figure 21: Patient at the end of treatment. The procumbency of the anterior teeth has been reduced without flattening the patient's beautiful profile.



Figure 20 (a–l): Intraoral pictures of the initial malocclusion, the stages of the orthodontic treatment, the end of treatment and 2 years post-treatment. The anterior brackets on the anterior teeth have been bonded 180°. Space in the arches has been created with stripping. Treatment time was 10 months.

© 2014 SIDO



Figure 22: Close-ups of the initial and final smile of the patient. Note the improved appearance of the upper and lower incisors.

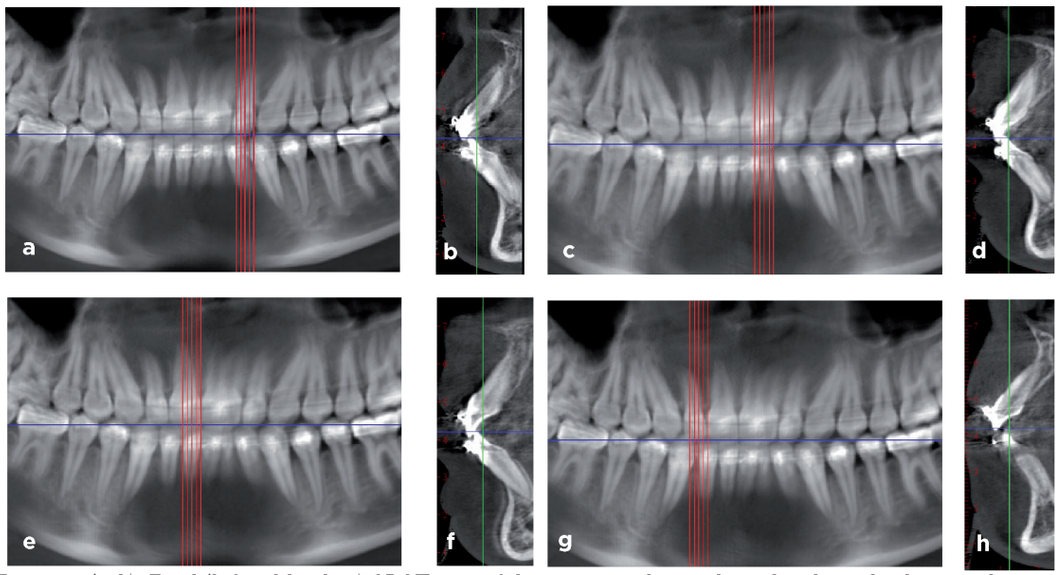

Figure 23 (a–h): Final (before debonding) CBCT scans of the anterior teeth to evaluate the relationship between the roots of the incisors and the premaxilla and the symphysis.



Figure 24: Initial facial photos of the patient. Note the slight mandibular retrusion.

and the forecasted final position of the roots of the anterior teeth must be accurately evaluated. In the final stage of treatment of detailing, the brackets may be repositioned in the normal way. This procedure may be indicated also for Class I malocclusions with upper incisor protrusion.

In *Figures 18–23* and *Figures 24–28*, two clinical cases treated as described are shown.

CONCLUSIONS

SWAs may present limits in controlling the torque of the anterior teeth in certain clinical and biomechanical situations. Changing move incisor roots. the anterior torque prescriptions to more effective and flexible values and rotating active self-ligating brackets as needed may improve biomechanical management and results in Class III malocclusions and in upper and/or lower incisor protrusion. CBCT scans should be routinely taken before and after treatment to accurately evaluate the anatomical boundaries in which to move incisor roots.

© 2014 SIDO



Figure 25 (a–l): Intraoral pictures of the initial malocclusion and the stages of the orthodontic treatment. The In-Ovation brackets on the upper anterior teeth have been bonded rotated 180°. No intermaxillary elastics have been used.

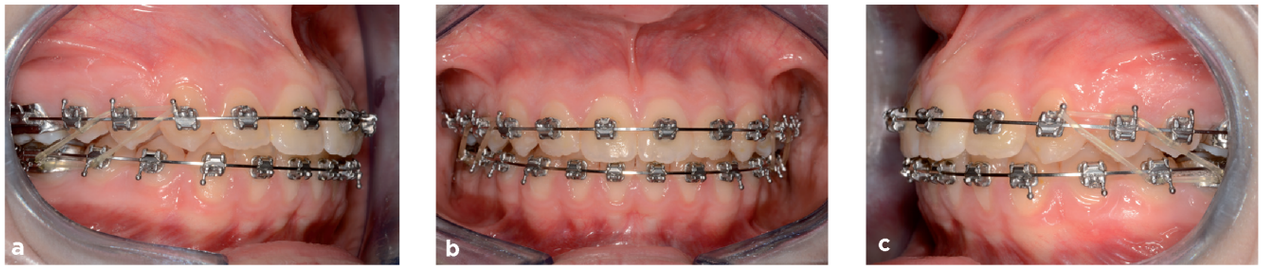

Figure 26 (a–c): At this stage of the treatment, brackets have been rebonded in the conventional position.

© 2014 SIDO

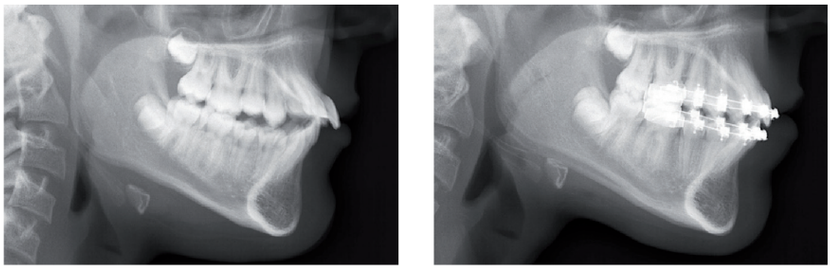

Figure 27: Close-ups of the initial and progress lateral cephalograms. Note the improved torque of the upper and lower incisors.

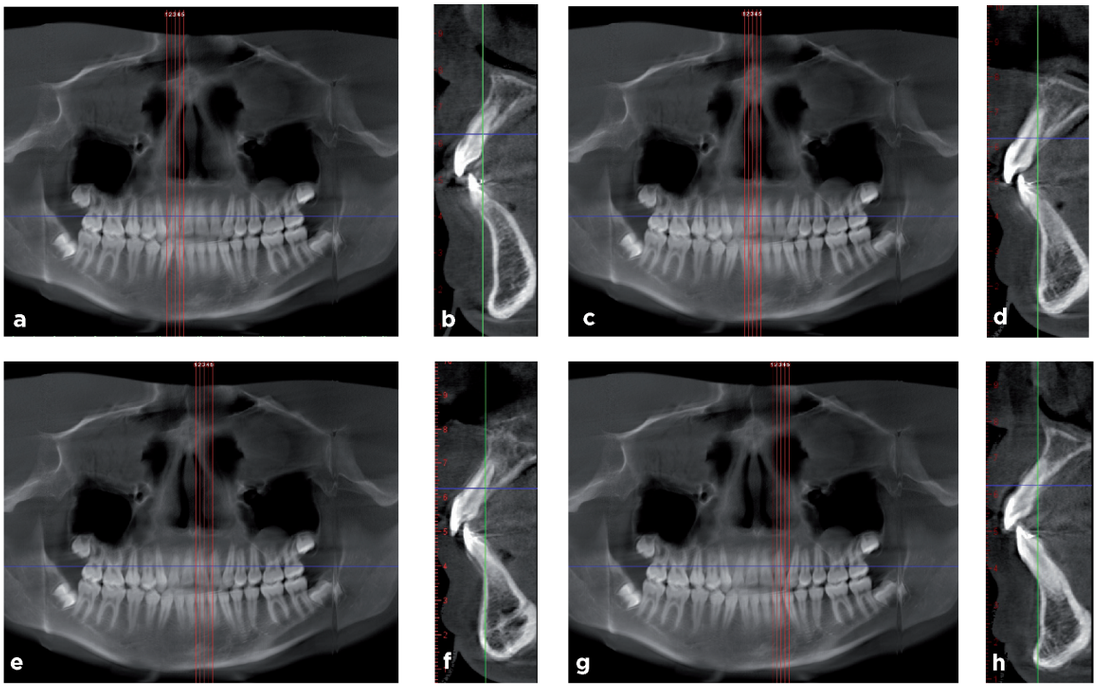

Figure 28 (a–h): Final CBCT scans of the anterior teeth to evaluate the relationship between the roots of the incisors and the premaxilla and the symphysis.

REFERENCE LIST

1. Andrews LF. The six keys to normal occlusion. *Am J Orthod* 1972;**62:**296–308.
2. Andrews LF. The straight-wire appliance: the extraction series. *J Clin Orthod* 1976;**10:** 99–114, 282–303, 360–379, 425–433, 507–529.
3. Roth HR. Five year clinical evaluation of the Andrews straight-wire appliance. *J Clin Orthod* 1976;**10:**836–850.
4. McLaughlin RP, Bennett JC. The transition from standard edgewise to preadjusted appliance systems. *J Clin Orthod* 1989;**23:**142–153.
5. Gick MR, Nóbrega C, Benetti JJ, Jakob SR, Zucchi TU, Arsati F. Comparative study of torque movement induced by self-ligation and conventional systems. *Orthod Sci Pract* 2012;**5:**37–46.
6. Secchi AG. Complete Clinical Orthodontics: Syllabus and Course Manual, DoctorOs AriesDue, 2012.

© 2014 SIDO



Vittorio Grenga

Private Practice
of Orthodontics,
Rome, Italy

Correspondence:
Via Apuania, 3 • 00162 Rome • Italy
e-mail: vigrenga@tin.it

X-RAY ODDITIES

Many times, when we see in our practice a radiograph, we have the opportunity to note images that may or may not influence directly our diagnosis and our treatment plan.
This feature of EJCO gives us the opportunity to show these images and to make some brief observations about them. The style is concise: the images largely speak for themselves.
Your suggestions for future topics as well as your comments will be very welcome.

A stubborn cuspid

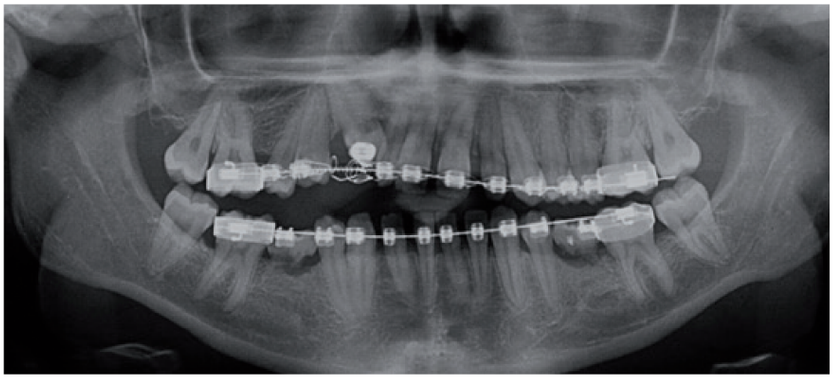

Figure 1: OPT after 12 months of orthodontic treatment to reposition the upper right impacted cuspid.

The patient, a 20-year-old girl, presented to the orthodontist with an impacted upper right cuspid. After an open surgical approach, traction was facilitated by an archwire attached to a button on the cuspid.
After 12 months of treatment, the cuspid was in the same position and the adjacent teeth showed typical signs of loss of anchorage *(Fig. 1)*.
At this time, cone beam computerized tomography (CBCT) was performed. The cross-sectional images through the area of interest showed the presence of a well defined radiolucent lesion lying on the cervical third of the root of the right upper cuspid. The inner portion of the lesion had a mottled appearance, suggesting that this portion of the lesion contained fibro-osseous like tissue *(Fig. 2 a–e)*.

OBSERVATIONS

Ankylosis is a frequent cause of failure in repositioning impacted canines[1].
The differential diagnosis of ankylosis needs to include invasive cervical root resorption (ICRR)[2].
ICRR is a rare, insidious and aggressive form of external root resorption. Typically it begins at a focal point on the surface of the root below the epithelial attachment in the clinical cervical area and progresses into dentine coronally, apically and circumpulpally, halting only at the predentine layer surrounding the pulp. It does not involve the pulp until very advanced stages. Thus, extensive dentinal destruction can occur in the complete absence of untoward symptoms [3,4].
The pathogenesis of ICRR is still unclear, but has been attributed to injury to the cementum at the cemento-enamel junction (CEJ), which exposes the underlying dentine. During an open surgical approach for the exposure of the impacted cuspid, mechanical damage to the CEJ could occur and may predispose the CEJ to the initiation of ICRR. Also, accidental leakage of orthophosphoric acid into the CEJ area might generate an ICRR lesion.

CONCLUSIONS

ICRR cannot always be estimated from conventional radiographs. If no movement of the impacted canine during orthodontic traction is detected, a CBCT should be considered to check for ICRR [5,6].

© 2014 SIDO

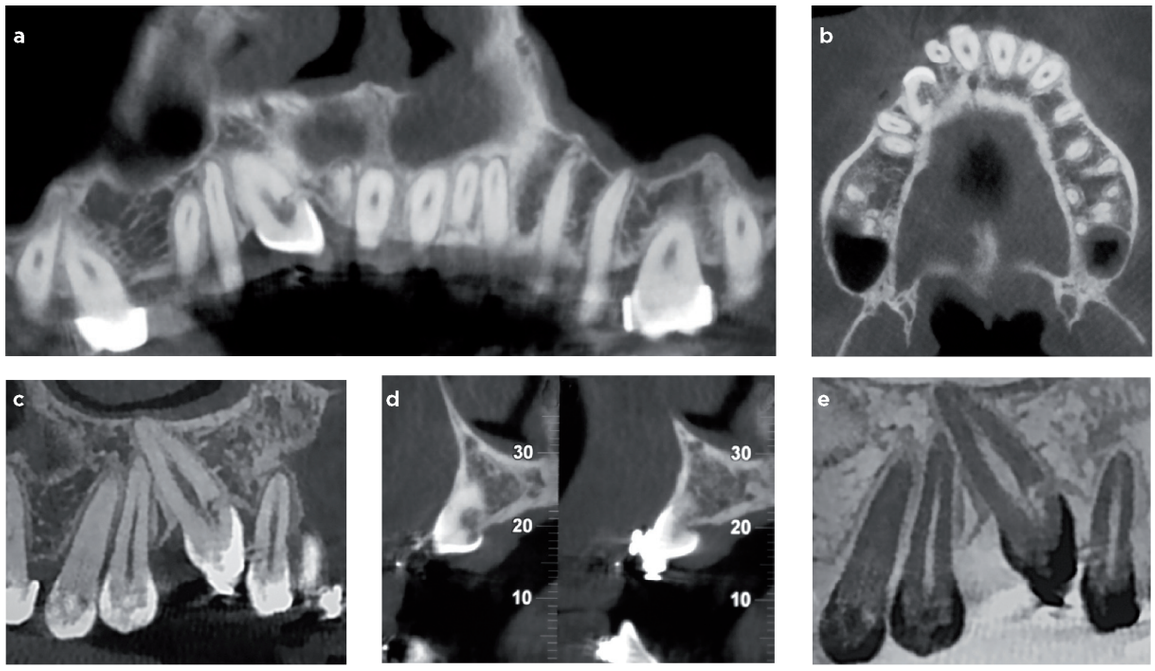

Figure 2 a-e: Cone beam computed tomography scans. Note the presence of a well defined radiolucent lesion lying on the cervical-third of the root of the right upper cuspid.

REFERENCE LIST

1. Becker A. The orthodontic treatment of impacted teeth. 3rd ed. Oxford: Wiley-Blackwell; 2012
2. Becker A, Abramovitz I, Chaushu S. Failure of treatment of impacted canines associated with invasive cervical root resorption. *Angle Orthod* 2013;**83:**870-876
3. Heithersay GS. Invasive cervical resorption: an analysis of potential predisposing factors. *Quintessence Int* 1999;**30:**83-95
4. Heithersay GS. Clinical, radiologic and histopatologic features of invasive cervical resorption. *Quintessence Int* 1999;**30:**27-37
5. Becker A, Chaushu S, Casap-Caspi N. Cone beam computed tomography and the orthosurgical management of impacted teeth. *J Am Dent Assoc* 2010; 141(suppl 3): 14S-18S
6. Patel S, Dawood A. The use of cone beam computed tomography in the management of external cervical resorption lesions. *Int Endod J* 2007;**40:**730-737

© 2014 SIDO

Hierarchy of Evidence



Bruno Oliva
Catholic University of Sacred Heart, Rome, Italy
Private Orthodontic Practice, Brindisi, Italy

Correspondence:
Via Garibaldi 144• 72022 Latiano (BR)
e-mail: brunoliva@tin.it

Bias: Any tendency to influence the results of a trial (or their interpretation) other than the experimental intervention[5].
Example: I want to know the average height of a population and I select a group of basketball players as a representative sample of the population. Despite repeated measurements the same error will always occur. The literature reports numerous types of bias which can influence a clinical study; Feinstein reports 32 types and Pocock 86 types[6].

Although the approach to clinical decision making and the Evidence-Based model are currently being widely discussed, I do not think we can disagree on the problem addressed by the model: how to identify and use the results of clinical trials in the management of the individual patient.
The pyramid showing the hierarchy of clinical trials is often included in publications or presentations almost as a proof of adherence to the Evidence Based model, but not always in an appropriate way. The hierarchy of evidence[1-3] is a scale indicating the reliability of clinical trials based on the possibility to control systematic errors (bias). The various types of studies listed in the pyramid refer to different ways of formulating the study, the so-called study design. A trial ranked high in the hierarchy can better control the systematic errors than one ranked at the bottom. This hierarchy takes into account only the quality of the clinical study regardless of its indication, i.e. its ability to answer a specific clinical question.
In the presence of a patient with maxillary canine displacement the following clinical questions are posed:

1. Which diagnostic imaging technique will allow the most accurate localization?
2. Once the displaced canine is accurately located, what is the probability of its spontaneous eruption?
3. Which surgical/orthodontic approach is the most effective?

It is therefore necessary to design a different hierarchy related to each clinical question concerning etiology, diagnosis, treatment or prognosis of the problem/disorder.
The hierarchy shown here is meant to give answers to questions concerning treatment. It is based on a more complex model which has recently been updated[4] and we will get back to it after having discussed the various types of clinical study design.

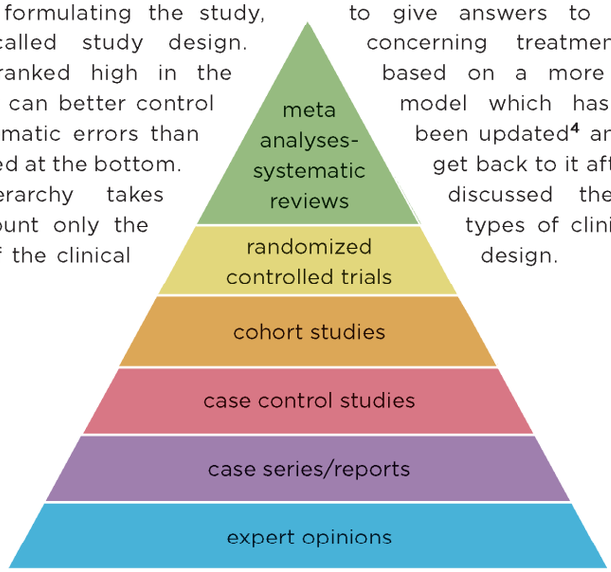

REFERENCE LIST

1. ADA. Center for Evidence Based Dentistry. Available from: http://ebd.ada.org/Default.aspx
2. Hierarchy of Evidence: Adapted from the Oxford Centre for Evidence-based Medicine - Levels of Evidence (March 2009). Available from: http://www.cebm.net/index.aspx?o=1025
3. Papadopoulos MA. Meta-analyses and orthodontic evidence-based clinical practice in the 21 century. *Open Dent J* 2010;**4:**92-123
4. OCEBM Levels of Evidence Working Group*. "The Oxford Levels of Evidence 2". Oxford Centre for Evidence-Based Medicine. http://www.cebm.net/index.aspx?o=5653
5. OCEBM Table of Evidence Glossary. Oxford Centre for Evidence-Based Medicine. http://www.cebm.net/?o=1116
6. Trial Clinici. Come interpretare e applicare I risultati di una ricerca scientifica. Bobbio M. Centro Scientifico Editore, Torino 1996

WE TESTED...

VECS™ palate expander







Accidental swallowing or aspiration of an activation key by patients is a life-threatening issue that should concern all orthodontists[1-4].
The VECS palate expander is immune to this problem because the handling of the large key takes place outside of the mouth and it cannot be swallowed by patients.
The activation screw-head has a diameter of 3 mm and is very easy to see. The key is inserted into the front of the expander and twisted similarly to the way a car key is turned.
The worm gear system does not turn back.

There are two different types of VECS: one with an expansion range of 0–10 mm and the other with an expansion range of 0–14 mm.
Both of them provide 0.2 mm of expansion with one full rotation of the activation key (360°).
Chair-side instructional time will actually be reduced and additional appointments for re-instruction visits will not be required.

The VECS palate expander is a modern, ergonomic device that is quick, safe and easy to use.

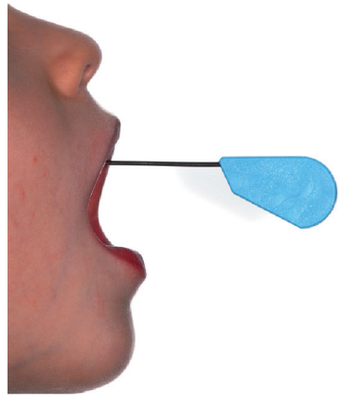

REFERENCE LIST

1. Monini Ada C, Maia LG, Jacob HB, Gandini LG Jr. Accidental swallowing of orthodontic expansion appliance key. *Am J Orthod Dentofacial Orthop* 2011;**140**:266–268.
2. Sfondrini MF, Cacciafesta V, Lena A. Accidental ingestion of a rapid palatal expander. *J Clin Orthod* 2003;**37**:201–202.
3. Nazif MM, Ready MA. Accidental swallowing of orthodontic expansion appliance keys: report of two cases. *ASDC J Dent Child* 1983;**50:**126–127.
4. Tripathi T, Rai P, Singh H. Foreign body ingestion of orthodontic origin. *Am J Orthod Dentofacial Orthop* 2011;**139:**279–283.

CONTACT INFORMATION:
Azure Ortho
20532 Crescent Bay Dr, Suite 100
Lake Forest, CA 92630
USA
www.AzureOrtho.com

© 2014 SIDO

Don't miss an opportunity to share your experience with your colleagues internationally

Call for papers

Landmark innovations have enabled clinicials to achieve considerable results, hence creating a challenge for the orthodontic pratictioner whose skills and experience are as important as his educational development.

EJCO welcomes clinical articles describing innovative techniques and procedures in orthodontics.

Manuscripts are peer-reviewed by an international forum of editors and reviewers.

Don't miss the opportunity to actively contribute to the improvements in techniques and clinical decision making by sharing your treatment philosophy and experience with your peers in this Journal.

SUBMIT to *www.ejco-journal.com*





SUBSCRIBE *now for the 2014 issues of EJCO*

The European Journal of Clinical Orthodontics
is published both online and in print three times a year

Online-only

can be purchased at *www.ejco-journal.com*
Access to content is immediate
after registration.

Print & online

individual subscribers can register
online or contact
editorialoffice@ejco-journal.com

Corporate subscribers

enjoy two *print* copies and a coupon code for full access to EJCO website for up to *20 users*. Users must *register* online using the coupon code to claim access as corporate subscriber. They will subsequently log in with their username and password and download EJCO full articles anytime.

SIDO members

Contact us to claim access as a member and receive your print copy of the Journal

and don't forget to sign up for EJCO alerts to be the first one to know when a new issue is available

SUBSCRIPTIONS	PRICE	TAX	VALIDITY
Individual Online-Only Access	€100	+ 22% VAT	2014
Individual Print & Free Online Access *(Europe)*	€261	***(1)***	2014
Individual Print & Free Online Access *(Rest of the World)*	€302	***(1)***	2014
Corporate and Institutional 2 Print copies & 20 Free Online Access ***(2)***	€2,500	***(1)***	2014
SIDO membership ***(3)***	contact SIDO Secretariat		
Single Article Purchase	€25	+22% VAT	permanent

(1) Delivery costs and applicable taxes are not included and will be calculated when placing an order.
(2) Online access must be activated through a coupon code for up to 20 users.
Value Added Tax will be added to the abovementioned prices where applicable.

The Official Journals of
THE ITALIAN SOCIETY OF ORTHODONTICS (SIDO)

Published by Springer Open

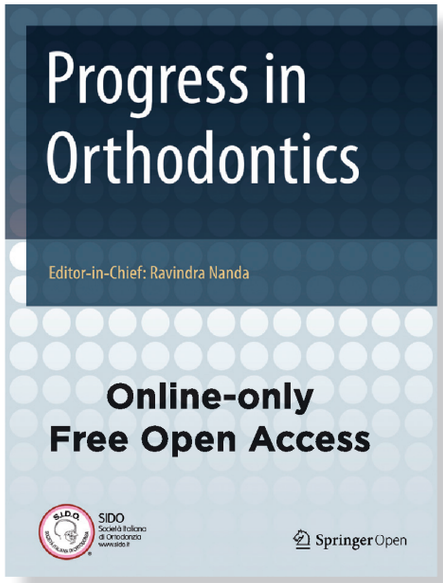

www.progressinorthodontics.com

A PREMIER RESEARCH JOURNAL

with the aim of fostering orthodontic basic research as well as innovative clinical techniques, with an emphasis on the following areas:
- mechanisms to improve orthodontics;
- clinical studies and control animal studies;
- orthodontics and genetics, genomics;
- temporo-mandibular-joint (TMJ) control clinical trials, as well as efficacy of orthodontic appliances and animal models.

Progress in Orthodontics will consider for publication only meritorious and original contributions, *i.e.:*
- Original articles reporting the findings of clinical trials, clinically relevant basic scientific investigations or novel therapeutic or diagnostic systems;
- Review articles on current topics;
- Techniques and novel clinical tools or exceptional levels of clinical competence may be considered;
- Articles of contemporary interest.

All accepted articles are published free of charge and made readily available online. Published by **Springer Open**

Editor-in-Chief
Ravindra Nanda (USA)
Editorial Director
Claudio Lanteri (USA)

Co-Editor
Felice Festa (Italy)
Associate Editors
Theodore Eliades (CH)
Carla Evans (USA)
Padhraig Fleming (UK)
Sunil Kapila (USA)
Mark Guenther Hans (USA)
Claudio Marchetti (Italy)
Adriano Piattelli (Italy)
Yijin Ren (NL)
Bhavna Shroff (USA)



Print and Online

www.ejco-journal.com

A NEW CLINICAL PUBLICATION

for the Orthodontic Practictioner publishing clinical cases based on a rationale summarizing evidence-based practice and techniques adopted by influential Orthodontists, sometimes commented by editorials and reviews.
News from the market and from publishers about innovative materials, devices and books a practictioner cannot do without.
All articles are peer-reviewed and published both online and in print at www.ejco-journal.com

Editor-in-Chief
Raffaele Schiavoni *(Italy)*
Associate Editors
- Hans-Peter Bantleon, *Austria*
- Alberto Caprioglio, *Italy*
- Giampietro Farronato, *Italy*
- Chung How Kau, *USA*
- Christos Katsaros, *Switzerland*
- Stavros Kiliaridis, *Switzerland*
- Claudio Lanteri, *Italy*
- Maurizio Manuelli, *Italy*
- Ravindra Nanda, *USA*
- Ramon Perera Grau, *Spain*

Editorial Director
Claudio Lanteri *(Italy)*
Co-Editor
Felice Festa *(Italy)*

Contributing Editors
- Carlo Bonapace *(editor of Who's Who column)*, *Italy*
- Gianluigi Fiorillo, *Italy*
- Vittorio Grenga *(editor of X-Ray Oddities column)*, *Italy*
- Bruno Oliva, (*editor of Literature Readings ... for Dummies*), *Italy*

45° SIDO INTERNATIONAL CONGRESS

SIDO
Società Italiana
di Ortodonzia
www.sido.it

Association founded in 1968

Members:	3.400
with Specialty in Orthodontics:	1.130
International Affiliates:	300

OCTOBER 9-11 2014 FLORENCE
FORTEZZA DA BASSO

Ortodonzia nell'adulto: approccio multidisciplinare

Adult Orthodontics: Multidisciplinary Approach



Per info: www.sido.it